




Aydın Dental Journal

Journal homepage: <http://dergipark.ulakbim.gov.tr/adj>



NEEDLE BREAKAGE DURING DENTAL ANESTHESIA IN THE MAXILLA: REPORT OF A CASE AND LITERATURE REVIEW

DergiPark
AKADEMİK

Gökhan GÜRLER¹, Çağrı DELİLBAŞI¹, İpek KAÇAR¹

ABSTRACT

Needle breakage is an uncommon complication during dental anesthesia. It generally occurs in inferior alveolar nerve block; however rare cases during maxillary injections have also been reported. There are different causative factors for needle breakage most of which can be preventable. Advanced radiological techniques are helpful to detect the exact localization of the broken fragment. Surgical removal of the needle is recommended since the broken piece may move deeper through the tissues. Here we report a case of a broken needle during maxillary dental anesthesia as well as radiological features and surgical treatment. Furthermore, we aimed to review the current literature regarding needle breakage during dental anesthesia.

Keywords: Broken needle, Dental anesthesia, Treatment, CBCT

ÖZET

İğne kırılması dental anestezi sırasında nadir görülen bir komplikasyondur. Daha çok Nervus alveolaris inferior blokajı sırasında oluşur, ancak maksiller enjeksiyonlar sırasında görülen az sayıda olgu bildirimleri de mevcuttur. İğne kırılması önlenemez pek çok farklı nedenlerle oluşabilir. İleri radyolojik teknikler kırılan iğne parçasının yerinin kesin olarak belirlenmesinde faydalıdır. Kırılan parçanın yumuşak dokular içinde hareket etmesi nedeniyle cerrahi olarak çıkartılması önerilmektedir. Bu olguda maksiller dental anestezi sırasında kırılan iğne parçasının radyografik özellikleri ve cerrahi olarak çıkartılması sunulmuştur. Bunun yanı sıra, dental anestezi sırasında iğne kırılmasına yönelik literatür derlemesi amaçlanmaktadır.

Anahtar Kelimeler: Kırık iğne, Dental anestezi, Tedavi, CBCT

¹ Istanbul Medipol University, Faculty of Dentistry, Department of Oral and Maxillofacial Surgery

INTRODUCTION

Despite the development of disposable anesthetic needles, there are still rare cases of needle breakage during dental anesthesia.¹ In majority of cases needle breakage was usually seen during the blockage of Inferior Alveolar Nerve (IAN). Augello et al. reported in a retrospective study that 70% of all dental needle breakages occurred during IAN anesthesia.² Repeated use of the same injector, sudden movement of the patient during injection, improper anesthesia technique or improper size of needles (thicker and longer needles) are the most encountered reasons of this undesirable situation.¹⁻⁵ Kronman et al. argued that a needle has to penetrate about 21 mm deep into the soft tissue to reach the mandibular foramen for a successful blockage of IAN.⁶ Needle breakage can also occur during local infiltration anesthesia aside from other regional anesthesia techniques.⁷

Treatment of a broken needle located inside the tissues is a challenging concept. Trying to take of a broken needle conversely can cause its moving into the deeper areas or may cause injuries of surrounding tissues.¹ Malamed has recommended leaving the broken fragment as long as the patient is asymptomatic.⁸ Although there is no consensus on optimal treatment when the patient is asymptomatic, it is agreed that removal of a broken needle is essential even if the patient has no symptoms.¹ The treatment choice is either removal of the fragment or follow-up of the patient. The first and the most important stage is determining the localization of the needle fragment properly.^{9,10} Conventional radiographs with or without metal markers, computed tomography (CT), cone beam computed tomography (CBCT) and c-arm fluoroscopy are the main imaging techniques. The most recommended

treatment for a broken needle in the oral region is removal of the fragment surgically under general anesthesia, although there is still a lack of consensus.

Here we aimed to present a case of needle breakage during local anesthesia in the maxilla and to review the present cases in the literature. In order to review the literature, articles published in English were searched in PubMed (<https://www.ncbi.nlm.nih.gov>) by using key words; broken needle, dental anesthesia, treatment, and CBCT. Only case reports and review articles and those published in English were taken into consideration.

CASE REPORT

A 45 year-old-female patient was referred to our clinic by her dentist with a complaint of broken needle fragment during maxillary anesthesia performed in order to fill the left first molar tooth a few days previously. The patient did not suffer from pain or swelling, but she has restricted mouth opening. Panoramic radiography revealed a broken needle fragment located through the retromaxillary region (Fig. 1).

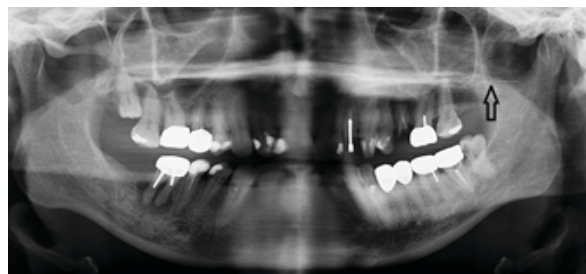


Figure 1: Panoramic view of the broken segment

To determine the exact localization, cone beam computed tomography (CBCT) was taken, which revealed broken needle fragment in the soft tissues of neighboring left maxillary tuberosity (Fig. 2, 3).

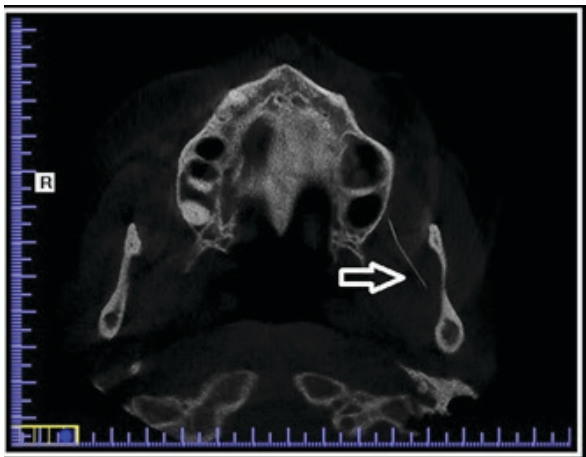
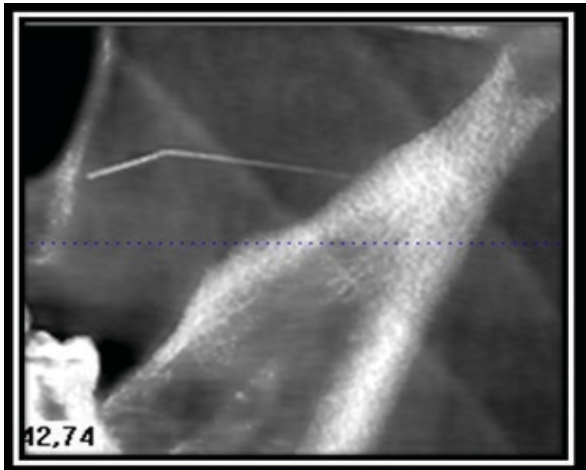


Figure 2: CBCT view of the broken segment

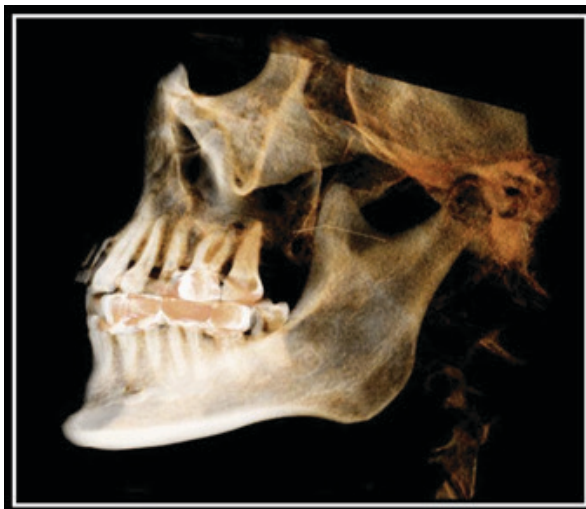

Figure 3: 3D reconstruction of the CBCT sections

A vertical incision in the tuber region was performed and partial thickness flap was raised under local anesthesia. Blunt dissection was carried out precisely through the retromaxillary region in order to avoid migration of the broken fragment. It was observed within the Bichat's fat pad. After removal of the needle incision was closed with a resorbable suture (Fig. 4). Postoperative course was uneventful.

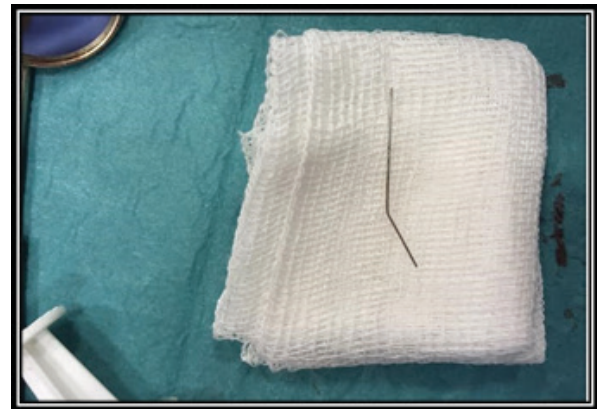


Figure 4: Removed broken needle

DISCUSSION

Needle breakage during dental anesthesia is still being an important problem. Despite the development of new dental materials, needle breakage is almost seen in the same percentage compared to past.¹ Metal syringes were the oldest version of the syringes until the introduction of stainless steel needles by Malamed in dental anesthesia.¹⁰ The newest computer controlled local anesthesia devices (C-CLAD) which are the end point in dental anesthesia have become more popular so far.^{10,11}

Augello et al. examined a total of 26 case reports that consisted of 64 cases of needle breakage during dental anesthesia between years 1966-2010. They reported that, 70% of the cases had

occurred during inferior alveolar nerve (IAN) block and all of the broken needles located in the pterygomandibular space. In addition, most of needles were in 30G diameter, which is considered as thin.² Catelani et al. also claimed that the needle breakage mostly occurred during IAN block and the fragments located in the pterygomandibular space.¹¹

In the literature, there has been no reported material defect or factory error as a causative factor for needle breakage; however; most of the broken needles have been reported to have a size of 30G.²

When such a complication occurs, localization of the broken fragment is the first step of treatment.¹¹ It can be helpful to mark the oral mucosa (by a marking pen) where needle penetrated.¹² It is advisable to refer the patients to an oral and maxillofacial surgeon immediately.¹² Thorough imaging is absolutely necessary to localize the fragment. CT and fluoroscopy are considered the most popular and current imaging methods.¹³ Neuronavigation techniques in order to find foreign bodies in oral region can be a proper option.¹³ This system has been used to locate a broken dental needle in the pterygomandibular space during local anesthesia. Brucelli and Bacci tried to use a c-arm fluoroscope for the same purpose and declared it as successful.^{14,15} Stein reported that using 3-D Navigation systems together with CBCT was another possible option. They used a custom-made interocclusal splint for stabilizing the position of the mandible to prevent migration of the needle.³ Gerbino et. al. also used this combination to remove a broken dental needle. However, reference tools which are being used in this image guided systems mainly were designed for stable tissues; hence, they cannot duplicate the movements of

dynamic organs perfectly, such as mandible.¹⁶ To overcome this problem, stabilizing the mandibular position by an interocclusal splint with neuronavigation has been advised.¹⁷⁻¹⁹

Using reference needles or metals is another simplifying way in imaging. Rifkind et. al. advised using 2 reference needles in combination with fluoroscopy in a case report.²⁰ Some authors suggest to use metal detectors or magnets in combination with radiographs as reference tools.²¹⁻²³ If a plain radiograph is used, at least two reference needles in different lengths have been advised.^{1,2,24,25} Besides, it has been suggested that radiographs should be taken in open-mouth position in order to prevent shift of reference tools.²⁴ In addition to these reference tools, adhesive markers can also be used.²⁶ Furthermore, intraoperative ultrasound is recommended to localize a broken dental needle.²⁷

It is still challenging to decide the best option for a broken needle in oral tissues; removing or keeping it as long as it's asymptomatic. Rifkind et al. drew attention to the risk of migration of broken fragment when trying to remove it. If it happens, there would be a need for a second surgery.²⁰ Migration of a broken needle to cervical spaces has been thought as the most dangerous complication during surgery.^{28,29} If the tip of a broken fragment is not visible, patient should be immediately directed to an oral and maxillofacial surgeon in order to prevent any possible migration. Thompson et al. argued that removing a broken dental needle is the best choice in treatment.³⁰ General opinion about this debate is to try to remove the broken fragment,³⁰⁻³² on the contrary, there is another opinion that claims, to keep the broken fragment in situ as long as it is asymptomatic.^{8,21} Frases and Moodie reported that they were reluctant to

remove the broken needle because of the risk of pushing it into deeper tissues and injure any vital/important structures.²⁹ For this reason, they supported to observe it in situ as long as it is asymptomatic. Although it is believed that there is a risk for injury of vital tissues by migration of the needle, there is no report showing any serious/life threatening conditions due to broken needle. However, there are some cases that showed a broken needle could migrate into pharyngeal spaces and caused dysphagia^{4,5,26,33} One important indication for removing a broken needle is the patient's psychology.⁴ Patients keep being irritated as long as they live with a broken needle inside their body. As a result, there is an agreement on removing the broken needle under general or local anesthesia by a specialist/oral and maxillofacial surgeon at early stages.^{2,15} We preferred to remove the broken needle in our patient to prevent its further movement. If there is a swelling or trismus that prevents mouth opening, operation should be delayed until symptoms subside.³ Trying to remove it under local anesthesia is not recommended, because of the muscle movements and the risk of further migration.^{31,32} In our case we removed the needle under local anesthesia since it did not migrate in to deeper tissues.

Complications associated with surgical removing of a broken needle, are challenging. Most usual complications are mild trisms and dysphagia. However, there are some uncommon cases that reported facial paralysis after surgical removal of a dental needle.² Because the unchanging rate of cases from past to the present, many authors gave some advises which should be followed by all clinicians when performing dental anesthesia. Kronman et al. showed that the most proper length for penetration is 21mm in a study in

cadavers.³⁴ Philbert et al. claimed that the needle penetrates into tissue approximately 25 mm to reach the medial aspect of mandibular ramus and lingula. They recommended to avoid using short needles in IAN block to prevent breakage especially in adults.³⁵ In addition, Brownbill et al. signed that 16 mm deepness in penetration is enough for an adequate IAN block in children, therefore, opposite to adults, using short needles in IAN block in children is proper.³⁶

Malamed showed that the breakage of a dental needle is mainly associated with the length and diameter. It was suggested that selection of proper needle should be made according to type of anesthesia. Using short needles should be avoided for IAN block in adults.⁸ Besides, 30G needles are not to be used in both children and in adults in IAN block. One should not bend dental needles before penetration into soft tissues nor should penetrate it to its hub, where this is the weakest point of the needle and it can totally disappear inside the tissue.⁸ We cannot comment on how needle was broken in our patient as this happened at somewhere else. Paying special attention to anxious patients is also critical to prevent them from sudden movement of their head. The access angle of dental injector is another important factor to prevent any needle breakage. If it is needed to change the angulation during injection, it is better to take the needle off the tissue.²

REFERENCES

- [1] Altay MA, Jee-Hyun Lyu D, Collette D, Baur DA, Quereshy FA, Teich ST, Gonzalez AE. Transcervical migration of a broken dental needle: a case report and literature review. *Oral Surg Oral Med Oral Pathol Oral Radiol.* 2014;118(6):e161-5.
- [2] Augello M, von Jackowski J, Grätz KW,

- Jacobsen C. Needle breakage during local anesthesia in the oral cavity--a retrospective of the last 50 years with guidelines for treatment and prevention. *Clin Oral Investig* 2011;15(1):3-8.
- [3] Stein KM. Use of Intraoperative Navigation for Minimally Invasive Retrieval of a Broken Dental Needle. *J Oral Maxillofac Surg* 2015;73(10):1911-6.
- [4] Marks RB, Carlton DM, McDonald S. Management of a broken needle in the pterygomandibular space: report of case. *J Am Dent Assoc* 1984;109(2):263-4.
- [5] Bhatia S, Bounds G. A broken needle in the pterygomandibular space: report of a case and review of the literature. *Dent Update* 1998;25(1):35-7.
- [6] Kronman JH, el-Bermani AW, Wongwatana S, Kumar A. Preferred needle lengths for inferior alveolar anesthesia. *Gen Dent* 1994;42(1):74-6
- [7] Bailey E, Rao J, Saksena A. Case Report: Fractured Needle in the Pterygomandibular Space Following Administration of an Inferior Dental Nerve Block. *Dent Update* 2015;42(3):270-2.
- [8] Malamed SF. *Handbook of Local Anaesthesia* 6th ed. St. Louis, MO. Mosby: 2012.
- [9] Zeltser R, Cohen C, Casap N. The implications of a broken needle in the pterygomandibular space: clinical guidelines for prevention and retrieval. *Pediatr Dent* 2002;24(2):153-6.
- [10] Malamed SF, Reed K, Poorsattar S. Needle breakage: incidence and prevention. *Dent Clin North Am* 2010;54(4):745-56
- [11] Catelani C1, Valente A, Rossi A, Bertolai R. Broken anesthetic needle in the pterygomandibular space. Four case reports. *Minerva Stomatol* 2013;62(11-12):455-63.
- [12] Baart JA, van Amerongen WE, de Jong KJ, Allard RH. [Needle breakage during mandibular block anaesthesia: prevention and retrieval]. *Ned Tijdschr Tandheelkd*. 2006;113(12):520-3.
- [13] Siessegger M, Mischkowski RA, Schneider BT, Krug B, Klesper B, Zöller JE. Image guided surgical navigation for removal of foreign bodies in the head and neck. *J Craniomaxillofac Surg* 2001;29(6):321-5.
- [14] Brucoli M, Deandreis M, Arcuri F, Benech A. Management of a needle breakage during third molar extraction with C-ARM digital fluoroscope. *J Craniofac Surg*. 201;23(5):1583-4.
- [15] Bacci C, Mariuzzi ML, Ghirotto C, Fusetti S. Local anesthesia needle breakage in a 5-year-old child during inferior alveolar nerve block with the Vazirani-Akinosi technique. *Minerva Stomatol*. 2012;61(7-8):337-40.
- [16] Gerbino G1, Zavattero E, Berrone M, Berrone S. Management of needle breakage using intraoperative navigation following inferior alveolar nerve block. *J Oral Maxillofac Surg*. 2013;71(11):1819-24.
- [17] Hoffmann J, Troitzsch D, Westendorff C, et al: Temporary intermaxillary fixation using individualized acrylic splints permits image-data-based surgery of the lower jaw and oropharynx. *Laryngoscope* 114:1506, 2004
- [18] Gonul E, Akboru M, Timurkaynak E: Orbital foreign bodies after penetrating gunshot wounds: Retrospective analysis of 22 cases and clinical review. *Minim Invasive Neurosurg* 42:207, 1999
- [19] Enislidis G, Wagner A, Ploder O, et al: Computed intraoperative navigation guidance: A preliminary report on new technique. *Br J Oral Maxillofac Surg* 35:271, 1997
- [20] Rifkind JB. Management of a broken needle in the pterygomandibular space following a Vazirani-Akinosi block: case report. *J Can Dent Assoc*. 2011;77:64.

- [21] Moore UJ, Fanibunda K, Gross MJ. The use of a metal detector for localisation of a metallic foreign body in the floor of the mouth. *Br J Oral Maxillofac Surg* 1993;31(3):191-2.
- [22] Johansson B, Krekmanov L. Fragment of broken instrument removed from field of operation by an electromagnet. *Br J Oral Maxillofac Surg* 1987;25(3):265-6.
- [23] Chittenden HB, Chandra A, Sandy CJ. Use of an electromagnet to retrieve a broken fascia needle during frontalis sling surgery. *Ophthal Plast Reconstr Surg* 2005;21(6):469-70.
- [24] Bump RL, Roche WC. A broken needle in the pterygomandibular space. Report of a case. *Oral Surg Oral Med Oral Pathol* 1973;36(5):750-2.
- [25] Bedrock RD, Skigen A, Dolwick MF. Retrieval of a broken needle in the pterygomandibular space. *J Am Dent Assoc* 1999;130(5):685-7.
- [26] Ho KH. A simple technique for localizing a broken dental needle in the pterygomandibular region. *Aust Dent J* 1988;33(4):308-9.
- [27] Crouse VL. Migration of a broken anesthetic needle: report of a case. *S C Dent J* 1970;28(9):16-9.
- [28] Amies A.B. Broken needles *Aust J Dent* 1951;55403-406.
- [29] Fraser-Moodie W. Location and localisation of metal in the tissues *Br J Oral Surg* 1966; 499-105
- [30] Thompson M, Wright S, Cheng LH, Starr D. Locating broken dental needles. *Int J Oral Maxillofac Surg* 2003;32(6):642-4.
- [31] Ethunandan M, Tran AL, Anand R, Bowden J, Seal MT, Brennan PA. Needle breakage following inferior alveolar nerve block: implications and management. *Br Dent J* 2007 14;202(7):395-7.
- [32] Nezafati S, Shahi S Removal of broken dental needle using mobile digital C-arm. *J Oral Sci* 2008;50(3):351-3.
- [33] Faura-Solé M, Sánchez-Garcés MA, Berini-Aytes L, Gay-Escoda C. Broken anesthetic injection needles: report of 5 cases. *Quintessence Int* 1999;30(7):461-5.
- [34] Kronman JH, el-Bermani AW, Wongwatana S, Kumar A. Preferred needle lengths for inferior alveolar anesthesia. *Gen Dent* 1994;42(1):74-6.
- [35] Philbert R, Hamilton B, Zola M. Management of needle breakage using intraoperative navigation following inferior nerve block. *J Oral Maxillofac Surg* 2014;72(4):653.
- [36] Brownbill JW, Walker PO, Bourcy BD, Keenan KM. Comparison of inferior dental nerve block injections in child patients using 30-gauge and 25-gauge short needles. *Anesth Prog* 1987;34(6):215-9.