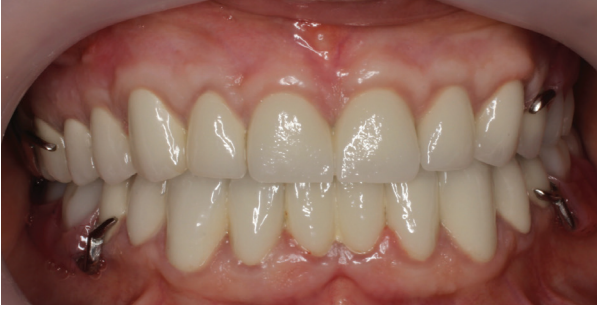



Resim 5: Tedavi bitimi sonrası alınan fotoğraf

TARTIŞMA

Kron boyu uzatma işlemlerinde gingival sağlığın sürdürülebilmesi için yapışık diş eti miktarı ve biyolojik aralığa dikkat etmek gerekmektedir.⁷⁻⁸ Ayrıca dental papillaların uygun konumda olabilmesi için aproksimal bölgede kemik kaldırılırken dişlerin kontakt noktasına olan mesafe dikkate alınmalıdır.⁹ Restorasyonların ve periodontal sağlığın uzun dönem başarısı için restorasyon marjini ile kemik kreti arasında mesafe en az üç mm olmalıdır.¹⁰ Bu vakada da bu mesafenin uygun şekilde oluşturulabilmesi için kemik redüksiyonu ile birlikte kron boyu uzatma işlemi yapılmıştır.

SONUÇ

Sonuç olarak kron boyu uzatma işlemi restorasyonların uzun dönem başarısı ve tatmin edici bir estetik sonuç sağlanması için kullanılan uygun bir yöntemdir. Bununla birlikte başarılı bir sonuç için hastanın uyumu ve yeterli seviyede oral hijyen alışkanlığına sahip olması önemlidir. Ayrıca estetik bölgelerde yeterli estetik ve fonksiyonel sonuçların alınabilmesi için multidisipliner çalışma gereklidir.

REFERANSLAR

1. M. Davarpanah, C. E. Jansen, F. M. A. Vidjak, D. Etienne, M. Kebir, and H. Martinez, "Restorative and periodontal considerations of short clinical crowns," *International Journal of Periodontics and Restorative Dentistry*, vol. 18, no. 5, pp. 425–433, 1998.

2. K. Pradeep, N. Patil, T. Sood, U. Akula, and R. Gedela, "Full mouth rehabilitation of severe fluorosed teeth with an interdisciplinary approach (6 handed dentistry)," *Journal of Clinical and Diagnostic Research*, vol. 7, no. 10, pp. 2387–2389, 2013.

3. S. Yeh and S. Andreana, "Crown lengthening: basic principles, indications, techniques and clinical case reports," *New York State Dental Journal*, vol. 70, no. 8, pp. 30–36, 2004.

4. J. Kois, "New paradigms for anterior tooth preparation: rationale and technique," *Oral Health*, vol. 88, pp. 19–30, 1998.

5. A. W. Gargiulo, F. M. Wentz, and B. Orban, "Dimensions and relations of the dentogingival junction in humans," *Journal of Periodontology*, vol. 32, no. 3, pp. 261–267, 1961.

6. J. S. Ingber, L. F. Rose, and J. G. Coslet, "The 'biologic width': a concept in periodontics and restorative dentistry," *Alpha Omegan*, vol. 70, no. 3, pp. 62–65, 1977

7. N. P. Lang and H. L'oe, "The relationship between the width of keratinized gingiva and gingival health," *Journal of Periodontology*, vol. 43, no. 10, pp. 623–627, 1972.

8. J. G. Maynard Jr. and R. D. Wilson, "Physiologic dimensions of the periodontium significant to the restorative dentist," *Journal of Periodontology*, vol. 50, no. 4, pp. 170–174, 1979.


9. D. P. Tarnow, A. W. Wagner, and P. Fletcher, "The effect of the distance from the contact point to the crest of bone on the presence or absence of the interproximal dental papilla," *Journal of Periodontology*, vol. 63, no. 12, pp. 995–996, 1992.

10. U. Bragger, D. Lauchenauer, and N. P. Lang, "Surgical lengthening of the clinical crown," *Journal of Clinical Periodontology*, vol. 19, no. 1, pp. 58–63, 1992.



Aydın Dental Journal

Journal homepage: <http://dergipark.ulakbim.gov.tr/adj>



CONSERVATIVE MANAGEMENT OF KERATOCYSTIC ODONTOGENIC TUMOR WITH MARSUPIALIZATION FOLLOWED BY ENUCLEATION: A CASE REPORT

DergiPark
AKADEMİK

Emrullah ÖZEN PhD DDS¹

ABSTRACT

Keratocystic odontogenic tumor (formerly odontogenic keratocysts) (KCOT) is an unique cyst because of its locally aggressive behavior, high recurrence rate and characteristic histological appearance. The present case report describes the conservative surgical management of a large

keratocystic odontogenic tumor in an adult patient with no evidence of recurrence at two years follow-up.

Keywords: *Keratocystic odontogenic tumor, marsupialization, acrylic stent obturator*

¹ Istanbul Aydin University, Faculty of Dentistry Department of Oral and Maxillofacial Surgery
Doi Num: 10.17932/IAU.DENTAL.2015.009/dental_v06i1002

MARSÜPYALİZASYONU TAKİBEN YAPILAN ENÜKLEASYON İLE KERATOKİSTİK ODONTOJENİK TÜMÖRÜN KONSERVATİF TEDAVİSİ: BİR OLGU SUNUMU

ÖZ

Keratosistik odontojenik tümör (eski adıyla odontojenik keratosist) (KCOT), lokalize agresif davranışa, yüksek nüks oranına ve karakteristik histolojik bir görünümüne sahiptir. Bu olgu sunumunda, erişkin bir hastada büyük

bir keratosistik odontojenik tümörün konservatif cerrahi tedavisi yapılmış ve iki yıllık takibinde nüks görülmemiştir.

Anahtar Kelimeler: Keratosistik odontojenik tümör, marsüpyalizasyon, akrilik stent obtüratör

INTRODUCTION

Keratocystic odontogenic tumor (formerly odontogenic keratocysts) (KCOT), defined by the World Health Organization as a benign neoplasm, is a unique cyst because of its locally aggressive behavior, high recurrence rate and characteristic histological appearance.

[1] KCOT's are more commonly found in the mandible than in the maxilla. It accounts for approximately 12-14% of all odontogenic cysts of the jaws. This tumor affects individuals of both genders, with a slight predilection for males, and shows a more incidence in the third decade of life.[2] Radiographic image, is most often unilocular or multilocular well-circumscribed radiolucent lesion, lined by smooth or scalloped margins with sclerotic borders. KCOT has presumably arisen from cell rests of the dental lamina or from offshoots of the basal cell layer of the oral epithelium[1]. The differential diagnosis involves odontogenic cyst, dentigerous cyst, and ameloblastoma. Signs and symptoms most frequently found include pain, abscess, swelling, infection and discharge, cellulitis, and trismus. A perceptible number of cases is diagnosed incidentally during regular dental inspections.[3]

The conservative treatment for this pathology includes marsupialization, decompression, enucleation, and curettage. More aggressive approach is based on osteotomy, lesion

resection, use of chemical agents like Carnoy's solution, cryotherapy with liquid nitrogen or peripheral osteotomy.[4] The type of treatment is controversial, but depends on innumerable factors including: Localization and size of the lesion; patient age; or whether the KCOT is recurrent or primary.

CASE REPORT

33 year-old male patient admitted to clinic for routine follow-up. After taking panoramic radiograph and examining intraorally, a unilocular radiolucent cystic lesion with sclerotic border in mandibular ramus region was diagnosed incidentally. (Figure 1a) Clinical examination revealed no pain, no intra and extra oral swelling, good plaque control, and no periodontal disease. After intraoral and radiographic examination, Cone Beam Tomography (CBCT) was requested for further examination. CBCT scan showed a cavity in the left mandibular ramus with a partial absence of lingual bone plate and part of the buccal bone wall preserved. (Figure 2) Incisional biopsy was done and at the same time impression for acrylic stent obturator was taken. (Figure 3) Histological diagnosis of cyst was established as keratocystic odontogenic tumor (KCOT). Control radiographs (Figure 1b, 1c, 1d) were taken every 6 months in 2 years follow-up. Supplementary enucleation was done when the cyst cavity was reduced.

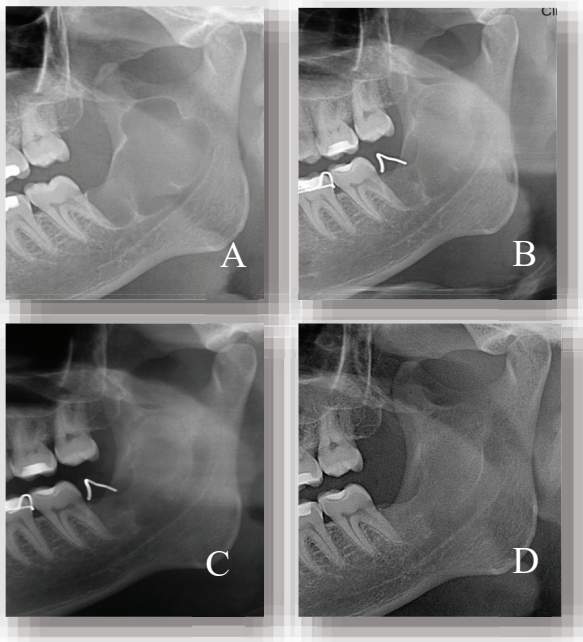


Figure 1: **a;** Pre-op panoramic radiograph showed a radiolucent area surrounded by a radiopaque border in mandibular ramus region. **b;** Follow-up panoramic radiograph 6 months after marsupialization. **c;** Follow-up panoramic radiograph 1 year after marsupialization. **d;** Follow-up panoramic radiograph 2 years after marsupialization.

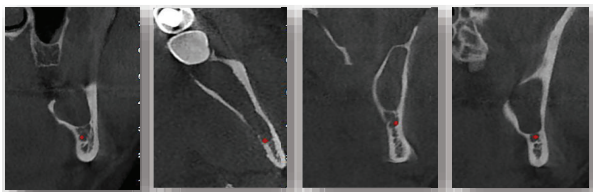


Figure 2: CBCT scan showed a cavity in the left mandibular ramus region (red point showed mandibular nerve)

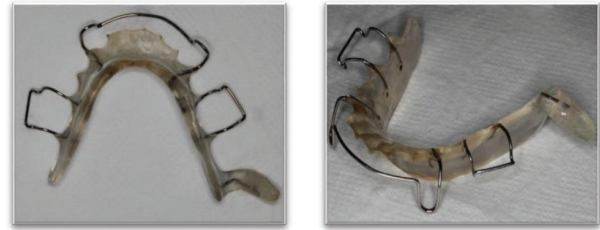

Figure 3: Acrylic stent obturator image

DISCUSSION

There was no complication and recurrence at 2 years follow-up. In addition, there was sign of healthy bone formation in the cavity. At 2 years follow-up radiograph, the radiolucency had reduced to almost completely. (Figure 1d) The treatment proposed was efficient in removing the KCOT with minimal surgical morbidity and optimal healing process.

CONCLUSION

Marsupialization has been considered as effective as a preliminary treatment for large KCOTs and it seems not to affect the recurrence tendency of this type of cyst. Contiguous structures such as tooth, the maxillary sinus or the inferior alveolar canal can be saved from damage. The procedure is highly successful in decreasing the cyst size before enucleation, and is useful to avoid extensive surgery, and is considered the first option for the treatment of large KCOT.^[5] It is important to notice that the decompression procedure was done with supplementary enucleation reduced the requirement of marginal resection. The authors advocated marsupialization as a definitive treatment for KCOTs in a certain number of cases. The authors showed that in some cases only the marsupialization for decompression, associated with hygiene and antibiotics were sufficient to promote the reduction of the lesion until its complete disappearance, followed by new bone formation.^[6]

In this case, because of the close relationship with mandibular canal, application of Carnoy's solution at cyst cavity was not preferred. There was no complication and recurrence at 2 years follow-up.

REFERENCES

1. de Avila, E.D., et al., *Relationship between the prevalence of the dentigerous cyst and the odontogenic keratocyst tumor and the current etiologic hypothesis*. J Craniofac Surg, 2009. 20(6): p. 2036-40.
2. Telles, D.C., et al., *Morphometric evaluation of keratocystic odontogenic tumor before and after marsupialization*. Braz Oral Res, 2013. 27(6): p. 496-502.
3. de Molon, R.S., et al., *Five years follow-up of a keratocyst odontogenic tumor treated by marsupialization and enucleation: A case report and literature review*. Contemp Clin Dent, 2015. 6 (Suppl 1): p. 152963.
4. Guler, N., K. Sencift, and O. Demirkol, *Conservative management of keratocystic odontogenic tumors of jaws*. ScientificWorldJournal, 2012. 680397 (10): p. 14.
5. Pogrel, M.A., *Decompression and marsupialization as a treatment for the odontogenic keratocyst*. Oral Maxillofac Surg Clin North Am, 2003. 15(3): p. 415-27.
6. Pogrel, M.A. and R.C. Jordan, *Marsupialization as a definitive treatment for the odontogenic keratocyst*. J Oral Maxillofac Surg, 2004. 62(6): p. 651-5.