




# Aydın Dental Journal

Journal homepage: <http://dergipark.ulakbim.gov.tr/adj>



## ENDODONTIC TREATMENT OF MANDIBULAR PREMOLAR WITH THREE CANALS USING CBCT

DergiPark  
AKADEMİK

Seda AYDEMİR<sup>1</sup>, Alper SİNANOĞLU<sup>2</sup>, Işıl Kaya BÜYÜKBAYRAM<sup>3</sup>, Göze ARUKASLAN<sup>1</sup>

### ABSTRACT

#### Background

Mandibular premolars generally have single root and single root canal. The frequency of mandibular premolars with two roots and three canals is extremely rare.

#### Objective

To present the management of a mandibular second premolar with two roots and three canals which was identified by cone-beam computed tomography (CBCT)

#### Case Description

13 years old male patient having pain in the right mandibular second premolar was referred for the endodontic treatment. The preoperative periapical radiograph showed the presence of two roots. After identification of three canals by CBCT two in the distal root and one in the mesial root, the endodontic treatment was performed. Radiographic follow-up of the case revealed no signs of periapical inflammation after one year.

#### Conclusion

Dental anatomical variations are important and must be identified preoperatively for a successful treatment outcome in endodontics. CBCT can be used for the preoperative diagnosis of complex root canal anatomy.

**Keywords:** anatomical variations, CBCT, endodontic treatment, mandibular second premolar

### ÖZET

#### Giriş

Alt çene küçük azı dişleri genellikle tek kök tek kanala sahiptir. Alt çene küçük azı dişlerinde çok nadir iki kök üç kanal gözlenmektedir.

#### Amaç

Konik ışıklı bilgisayarlı tomografi (KIBT) kullanılarak iki kök üç kanallı olduğu tespit edilen alt çene ikinci küçük azı dişine yapılan kök kanal tedavisinin sunulmasıdır.

#### Olgu sunumu

13 yaşındaki erkek hasta sağ alt ikinci küçük azı dişinde ağrı şikayeti ile kliniğimize başvurmuştur. İşlem öncesi alınan periapikal radyografide dişin iki köklü olduğu gözlenmiştir. KIBT yardımıyla ikisi distal kökte bir tanesi de mezial kökte olmak üzere toplam üç kanal varlığı tespit edilmiş ve sonrasında endodontik tedavi gerçekleştirilmiştir. 1 yıl sonra alınan kontrol radyografisinde periapikal bölgenin sağlıklı olduğu görülmüştür.

#### Sonuç

Endodontik tedavinin başarılı olabilmesi için dişteki anatomik varyasyonların işlem öncesinde tespit edilmesi önemlidir. KIBT işlem öncesinde karmaşık kök kanal anatomisine sahip dişlerdeki varyasyonların tespitinde kullanılabilir.

**Anahtar Kelimeler:** Alt çene ikinci küçük azı dişi, anatomik varyasyonlar, endodontik tedavi, KIBT

<sup>1</sup> Kocaeli University, Faculty of Dentistry, Department of Endodontics, Kocaeli, Turkey.

<sup>2</sup> Kocaeli University, Faculty of Dentistry, Department of Oral and Maxillofacial Radiology, Kocaeli, Turkey.

<sup>3</sup> Istanbul Aydın University, Faculty of Dentistry, Department of Endodontics, Istanbul, Turkey

## INTRODUCTION

Missed root canals are the common reason for the failure of endodontic treatment. Root canals are often left untreated because of clinician's lack of recognize about their presence, especially in teeth that has complex root canal morphology.<sup>1</sup> For this reason, the clinician should be informed about the possible variations in canal anatomy.

Mandibular second premolars generally have single root and single root canal.<sup>2</sup> Although extra canals in mandibular second premolars with multiple roots have been posted in literature these cases are extremely rare.<sup>3</sup> Slowey<sup>4</sup> stated that endodontic treatment of mandibular second premolar was the most complicated one due to the variations in canal anatomy

CBCT can be used for the preoperative diagnosis of complex root canal anatomy. The conventional intraoral radiograph gives two-dimensional (2D) image of the root canal system. However, CBCT images provide three-dimensional imaging. CBCT images can also allow the clinician to modify endodontic access cavity design in order to find extra canals.

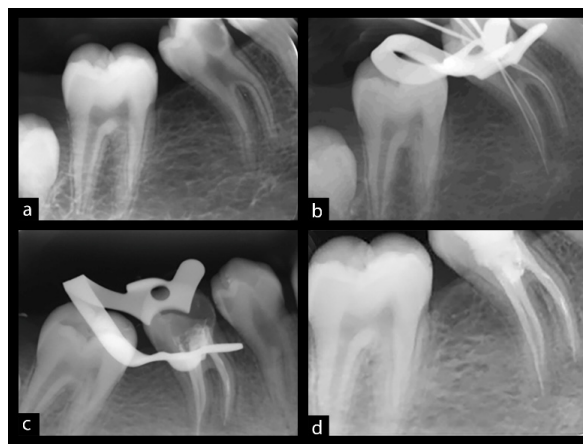
CBCT is not specified as a standard method in endodontics for showing of root canal anatomy. Using CBCT may be indicated where conventional intraoral radiographs show equivocal or inadequate information for planning treatment. Therefore, uses of this advanced imaging facilitate management of complex cases such as a premolar with three root canals.<sup>5</sup>

In this case report, successful endodontic treatment of the uncommon anatomy of a

mandibular right second premolar with two roots and three canals which were identified via CBCT and one- year follow-up findings was presented.

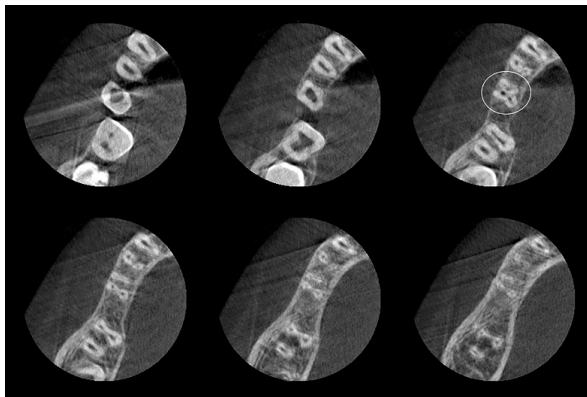
## CASE REPORT

A 13 years old male patient was applied to Kocaeli University, Faculty of Dentistry with pain in the right mandibular posterior region. An intraoral clinical examination and preoperative periapical radiograph showed the deep approximal caries lesion in the right mandibular second premolar. The pain was spontaneous and ceased only with analgesics. The probable diagnosis was an acute pulpitis and the endodontic treatment was indicated. Treatment plan was explained to the patient and consent obtained.



**Figure 1.** A: Pre-operative radiograph of right mandibular second premolar. B: Working length-determination radiograph demonstrating three root canals. C: Post-operative radiograph. Note three obturated root canals. D: Follow-up radiograph taken after one year.

The preoperative periapical radiograph [Figure 1a] showed the presence of two roots. Then cone-beam computed tomography scan was performed at 0.1 mm<sup>3</sup> voxel in order to investigate the cross-sectional morphology (Promax 3D Max, Planmeca Oy, Helsinki, Finland). The smallest field of view (FOV) was chosen as 5 x 5 cm. From orifice to apex, cross sectional morphology revealed the presence of three canals with two in the distal root and one in the mesial root [Figure 2].



**Figure 2** CBCT axial scan of mandibular second premolar with three canals.

Local anesthesia was applied (3% lidocaine with 1:100000 adrenaline) and a rubber dam was placed. The access cavity was prepared with a high-speed handpiece. After removing all coronal interference, the root canals were located and patency was obtained using a size #10 K-file (Mani Inc. Japan). The working lengths were established using an apex locator (Raypex 6, VDW, Germany) and a periapical radiograph [Figure 1b].

The endodontic treatment was performed with Protaper rotary instruments (Dentsply, Maillefer; Switzerland). The root canals were irrigated with 2.5 % sodium hypochlorite. After drying the canals with paper points, the canals dressed with calcium hydroxide paste

(Sultan Chemists Inc. Englewood, NJ, USA) and the access cavity was sealed with Cavit (3M ESPE, Seefeld, Germany). Ten days later, no clinical and radiographic symptoms were observed. Radiograph was taken with master cones in all canals. The root canals were obturated with gutta-percha and AH Plus (Dentsply, Maillefer; Switzerland) resin based sealer using cold lateral condensation technique. A final radiograph was taken to confirm obturation [Figure 1c]. And post endodontic restoration was performed with composite resin (Filtek Z250, 3M ESPE Seefeld, Germany) Radiographic follow-up of the case revealed no signs of periapical inflammation after one year [Figure 1d]

## DISCUSSION

Before initiating endodontic treatment, the actual number of root canals cannot be correctly identified.<sup>6</sup> The optimum expansion of the access cavity is necessary for identification of the orifices.<sup>5</sup> Examination of the pulp chamber floor by using small K-file tip was also proposed to detect the location of orifices.<sup>6</sup> In the present case the access cavity could not be prepared as proposed due to the narrow alignment of the orifices and Also the use of loop was insufficient.

Several diagnostic steps are essential for the definition of extra canals in mandibular second premolars. As a basic principle, Slowey<sup>4</sup> suggested good quality preoperative radiographs for discovering the additional root canals. Fischer & Evans<sup>7</sup> stated that the shape, position and relative outline of the suspected root and the periodontal ligament space should be evaluated carefully for identification of such anomalies like an extra root or root canal. Alberquerque et al.<sup>8</sup> recommended correct explanation of angled

radiographs, accessing suitable cavity, and a comprehensive exploration of tooth. Use of apex-locator combined with periapical radiograph for accurate working length determination was also suggested by Kim et al.<sup>9</sup> We performed the same approach Working length was successfully determined and the intraoperative radiograph was able to show two root canals confined in the distal root. Nevertheless, due its 2D limitation, it was not possible to investigate the mesial root canal morphology.

CBCT imaging has been used in endodontics to study root canal morphology which reveals teeth's actual canal number. The potent dose of CBCT scanners can be changed and the radiation dose can be reduced using a smaller FOV. It was reported that choice of FOV has a significant influence on root canal visibility.<sup>10</sup> In this case, the smallest FOV setting was used for CBCT scan in order to investigate the number of root canals.

## **CONCLUSIONS**

Successful endodontic treatment needs detailed knowledge of variations of root canal anatomy. The presence of extra root canals should be investigated for each tooth treated endodontically. CBCT can be used as a useful tool in the accurate diagnosis of complex root canal anatomy.

## **REFERENCES**

- [1] Cohen AS, Brown DC. Pathways of the Pulp. In: Cohen S, Burns RC. Orofacial dental pain emergencies: endodontic diagnoses and management. 8th ed. Boston: Mosby, 2002: 31-75.
- [2] Zillich R, Dowson J. Root canal morphology of mandibular first and second premolars. *Oral Surg* 1973;36:738-44.
- [3] Prakash R, Nandini S, Ballal, S, Kumar SN, Kandaswamy D. Two-rooted mandibular second premolars: Case report and survey. *Indian J Dent Res* 2008;19:70-3.
- [4] Slowey RR. Root canal anatomy- Road map to successful endodontics. *Dent Clin North Am* 1979;23:555-73.
- [5] Patel S, Dawood A, Ford TP, Whaites E. The potential applications of cone beam computed tomography in the management of endodontic problems. *Int Endod J* 2007; 10:818-30.
- [6] Poorni S, Karumaran C, Indira R. Mandibular first premolar with two roots and three canals. *Aust Endod J* 2010;36:32-4.
- [7] Fischer GM, Evans CE. A three-rooted mandibular second premolar. *Gen Dent* 1992; 40:139-40.
- [8] Alberquerque D, Kottoor J, Hammo M. Endodontic and clinical considerations in the management of variable anatomy in mandibular premolars: a literature review. *BioMed Res Int* 2014; 512574.
- [9] Kim E, Marmo M, Lee CY, Oh NS, Kim IK. An in vivo comparison of working length determination by only Root-ZX apex locator versus combining Root-ZX apex locator with radiographs using a new impression technique. *Oral Surg Oral Med Oral Pathol Oral Radiol Endod* 2008;105:79-83.
- [10] VenskutonisT, Plotino G, Juodzbaly G, Mickevičienė L. The importance of cone-beam computed tomography in the management of endodontic problems: a review of the literature. *J Endod* 2014; 40:1895-901.