




# Aydın Dental Journal

Journal homepage: <http://dergipark.ulakbim.gov.tr/adj>



## **RUSSELL-SILVER SYNDROME: A CASE REPORT**

**DergiPark**  
AKADEMİK

*Dr. Gülşah BALAN<sup>1</sup>, Prof. Dr. Serap AKYÜZ<sup>1</sup>*

### ABSTRACT

In 1953 and 1954, Silver and Russell independently described groups of small children whose pregnancies had complicated by intrauterine growth retardation with a both genetically and clinically heterogeneous disorder named Russel Silver Syndrome [RSS/SRS; OMIM 180860]. This case report describes the dental complications of the syndrome. A 4-year-old girl diagnosed with RSS at the Medical Faculty Hospital of Marmara University was directed to Marmara University Department of Pediatric Dentistry for dental examination. Severe dentin caries and pulpitis were detected in many teeth of the primary dentition as an indication of the child being in the high caries risk group (dft/dfs = 13/37). RSS-diagnosed children first experience nutritional difficulty and later face severe dental caries as a consequence.

**Keywords:** *Russel Silver Syndrome, hypoglicemia, severe dental caries*

### ÖZET

Russel Silver Sendromu [RSS/SRS; OMIM 180860], ilk defa 1953 ve 1954 yıllarında Russel&Silver tarafından tanımlanan, intrauterin ve post natal büyüme geriliği ile karakterize genetik ve klinik farklı fenotipik özellikler sergileyen bir gelişim bozukluğudur. Bu olgu sunumunun amacı RS sendromunun dental komplikasyonlarını tanıtmaktır. Marmara Üniversitesi Tıp Fakültesi Hastanesinde RSS tanısı konan ve dental muayenesi için kliniğimize yönlendirilen 4 yaşında kız çocuk şiddetli dental çürükleri nedeniyle yüksek çürük risk grubu (dft/dfs=13/37) olgusu olarak değerlendirildi. RSS tanısı alan ve beslenme güçlüğü yaşayan bebekler hipoglisemi riskine karşı sık ve yüksek glikoz takviyeli öğün tüketmektedirler. Önerilen diyetin alışkanlık haline geldiği ve ağız hijyenin sağlanamadığı bu çocuklarda dişlerin şiddetli bir şekilde çürütmesine neden olmaktadır.

**Anahtar Kelimeler:** *Russel Silver Sendromu, hipoglisemi, şiddetli dental çürük*

<sup>1</sup> Department of Pediatric Dentistry, Marmara University Faculty of Dentistry. Istanbul - TURKEY

## **INTRODUCTION**

Russell - Silver syndrome [RSS/SRS; OMIM 180860] is a pattern of malformation first described by Silver et al., in 1953 1 and then by Russell in 1954 2, characterized by intrauterine and postnatal growth retardation with both genetic and clinical findings. Main genetic defects found are at the epigenetic level: hypo-methylation of the imprinting control region 1 on 11p15 (44% of cases) is associated with a severe phenotype, maternal uniparental disomy of chromosome 7 (5–10% of cases) comes with a mild phenotype<sup>3</sup>, means of reduction the expression of the main fetal growth factor. The incidence of the disorder is one in approximately 100,000 live births. Most of the SRS cases are sporadic and both genders are equally affected.

Diagnosis is based on the variable combination of the following characteristics: short stature, underweight, relative macrocephaly, a typical small triangular face, asymmetry of the limbs and several minor anomalies such as blue sclera, webbed fingers and fifth-finger clinodactyly. 3, 4 Café au lait macules are the most common cutaneous manifestations.<sup>5</sup> Other features include learning and motor-coordination difficulties, high-pitched voice, and fasting hypoglycemia. Rare manifestations are cardiac or genitourinary defects and malignant conditions.<sup>6</sup> The growth failure in RSS is often associated with very low body mass index and significant feeding challenges that cause a failure to thrive. 7 Most patients have a favorable prognosis. Enteral way may be necessary for individuals who cannot tolerate oral feedings.

Due to the late closure of the anterior fontanelle, craniofacial symptoms include the typical features 8-10; small facial height, facial asymmetry, retruded positioning of the mandible, severe crowding due to the small jaw, down-turned mouth corners, overbite of more than 4.0 mm, dental arch width below the

norm 8. There is no report of delayed eruption of permanent dentition, congenital missing teeth, asymmetry of dental arch form 8.

## **CASE REPORT**

A 4-year-old girl genetically diagnosed with RSS was referred to the Marmara University Department of Pediatric Dentistry in 2016 with the complaint of pain and reduced chewing ability. The clinical appearance has a typical phenotype of RSS with a characteristic small triangular face with a prominent forehead and micro-gnathia with retro-gnathic mandibula. Genetic testing was performed and hypo-methylation of the paternal 11p15 imprinting control region 1 (ICR1) on H 19 gene has been found as confirmatory of the clinical findings. The body mass index of the 4-year-old girl was found to be weak (10.46 kg/m<sup>2</sup>) with low weight (8.1 kg) and with short stature (88 cm), as shown in Figure 1.



Figure 1. Picture showing the short stature of the 4-year-old child and her healthy 2-year-old brother.

Asymmetry of the limbs, high-pitched voice, fifth finger clinodactyly (Figure 2) and blue sclera are the other clinical findings of the patient, however there were no physical features such as café au lait macules or genitourinary defects. Learning and motor-coordination difficulties have not been reported for this case, either.

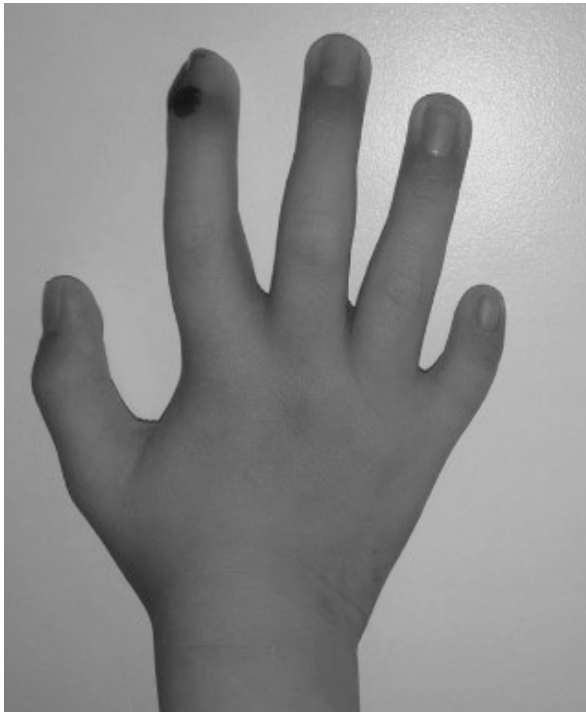

Figure 2. Fifth finger clinodactyly.

Petite triangular face with a prominent forehead, backwards ears, downturned mouth are found as the typical maxillofacial appearance of the syndrome, besides deep bite and micro-gnathia with retro-gnathic mandibula (Figure 3-4).

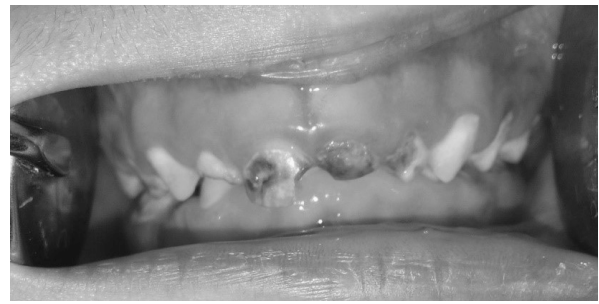

Figure 3. Characteristic intraoral features of the syndrome; deep bite and overjet.

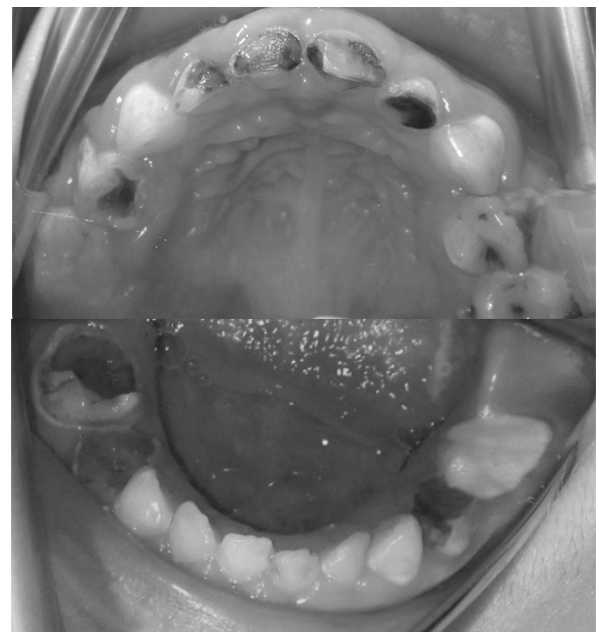

Figure 4. Intraoral pictures represent severe dental caries.

A mild crowded primary teeth progress in a normal time of dentition. The radiologic examination without cephalometric analysis was done for the permanent teeth to search for the dental anomalies which are not present for the case (Figure 5). Caries presence was evaluated by using the WHO criteria 11 and decayed-filled teeth and surface score (dft/dfs) were calculated 13/37, respectively. Thus, the child is at a high caries risk level for her age and with systemic requirements.

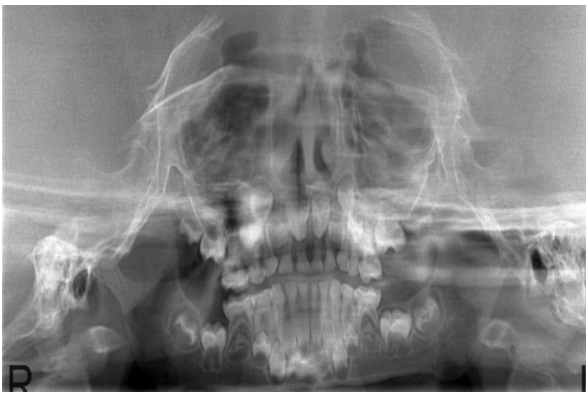

Figure 5. Panoramic X-Ray of the patient.

The parents were instructed on the dietary intake and also informed on misconceptions of feeding during the night. Oral hygiene manifestations were highlighted with brushing practice. Topical applications of fluoride varnish were suggested every 3 months and CCP-ACP gel (MI Paste, GC) for daily usage. Restorative treatments were performed for carious lesions in a minimally invasive manner.

## **DISCUSSION**

Russel Silver Syndrome is characterized by intrauterine and postnatal growth retardation both genetic and clinically identified with a variety of difficulties. Infant feeding practice is the major complication affected by maxillofacial morphology and muscle weakness which make the breastfeeding more complicated. In addition, there is a critical risk of development of hypoglycemia as inadequate cerebral glucose supply can lead to neurological impairments such as mental retardation or epilepsy. 12 Pediatric endocrinology services recommend a high glucose supplement to these children at frequent intervals. In our case report, the infant was fed with sweetened milk products and oral nutritional supplements every 4 hours a day, even at night, which has been on-going as a habit.

Amount of glucose and the frequency of consumption seem to be a significant contributor to the cariogenicity of the diet 13, common risk factors for the caries progression for both primary and permanent dentition. However, preventing dental decay is the most challenging in children with the systemic requirements. Promotable oral hygiene is as important as dietary facts which eliminates the biofilm. Moreover, the maxillofacial characteristics of the syndrome such as petite face and small jaw make the oral hygiene unmanageable within the usual methods.

RSS diagnosed children confront with malnutrition because of feeding difficulties and frequent intermittent meals are recommended to overcome the complications. Besides the gastroenterology, nutritional and endocrinologic consultations 4, the dental supportive care is one of the essential facts that should not be disregarded.

## REFERENCES

- [1] Silver HK, Kiyasu W, George J, Deamer WC. Syndrome of congenital hemihypertrophy, shortness of stature, and elevated urinary gonadotropins. *Pediatrics*. 1953;12(4):368-76.
- [2] Russell A. A syndrome of intra-uterine dwarfism recognizable at birth with craniofacial dysostosis, disproportionately short arms, and other anomalies (5 examples). *Proc R Soc Med*. 1954;47(12):1040-4.
- [3] Binder G, Begemann M, Eggermann T, Kannenberg K. Silver-Russell syndrome. *Best Pract Res Clin Endocrinol Metab*. 2011;25(1):153-60.
- [4] Price S, Stanhope R, Garrett C, Preece M, Trembath R. The spectrum of Silver-Russell syndrome: a clinical and molecular genetic study and new diagnostic criteria. *Journal of medical genetics*. 1999;36(11):837-42.
- [5] Hansen KK, Latson LA, Buehler BA, Latson LA. Silver-Russell syndrome with unusual findings. *Pediatrics*. 1987;79(1):125-8.
- [6] Wee SA. Russell-Silver syndrome. *Dermatology online journal*. 2007;13(1):16.
- [7] Blissett J, Harris G, Kirk J. Feeding problems in Silver-Russell syndrome. *Developmental Medicine & Child Neurology*. 2001;43(1):39-44.
- [8] Sato C, Ogawa T, Tsuge R, Shiga M, Tsuji M, Baba Y, et al. Systemic and maxillofacial characteristics of 11 Japanese children with Russell-Silver syndrome. *Congenit Anom (Kyoto)*. 2016;56(5):217-25.
- [9] Bergman A, Kjellberg H, Dahlgren J. Craniofacial morphology and dental age in children with Silver-Russell syndrome. *Orthodontics & Craniofacial Research*. 2003;6(1):54-62.
- [10] Kotilainen J, Hölttä P, Mikkonen T, Arte S, Sipilä I, Pirinen S. Craniofacial and dental characteristics of Silver-Russell syndrome. *American Journal of Medical Genetics*. 1995;56(2):229-36.
- [11] World Health O. Oral health surveys: basic methods: World Health Organization; 2013.
- [12] Flykanaka-Gantenbein C. Hypoglycemia in childhood: long-term effects. *Pediatr Endocrinol Rev*. 2004;1 Suppl 3:530-6.
- [13] Touger-Decker R, van Loveren C. Sugars and dental caries. *Am J Clin Nutr*. 2003;78(4):881S-92S.