



CASE REPORT

# Multidisciplinary approach to a subgingivally fractured incisor tooth: A case report



Doğru Ömür Dede<sup>a</sup>, Emine Şen Tunç<sup>b</sup>, Ahmet Umut Güler<sup>c\*</sup>,  
Sebahat Yazıcıoğlu<sup>d</sup>

<sup>a</sup> Department of Prosthodontics, Faculty of Dentistry, Ondokuz Mayıs University, Samsun, Turkey

<sup>b</sup> Department of Pediatric Dentistry, Faculty of Dentistry, Ondokuz Mayıs University, Samsun, Turkey

<sup>c</sup> Department of Prosthodontics, Faculty of Dentistry, İstanbul Aydın University, İstanbul, Turkey

<sup>d</sup> Department of Orthodontics, Faculty of Dentistry, Ondokuz Mayıs University, Samsun, Turkey

Received 30 January 2011; Final revision received 5 April 2011

Available online 14 February 2013

## KEYWORDS

all-ceramic crown;  
crown-root fracture;  
dental trauma;  
orthodontic  
extrusion;  
post core

**Abstract** This case report describes a multidisciplinary approach using orthodontic forced eruption to facilitate prosthetic restoration of a subgingivally fractured maxillary permanent central incisor. A 14-year-old male patient presented at the pediatric dental clinic due to unesthetic appearance and for management of a fractured maxillary right central incisor tooth. Intraoral examination revealed that the maxillary right central incisor had sustained a crown-root fracture with pulp exposure. We treated the tooth endodontically and performed orthodontic root extrusion with a modified Hawley appliance prior to prosthetic rehabilitation. Approximately 2–3 mm of extrusion of the tooth was obtained within 8 weeks. A fiber post was then inserted into the root canal, and final restoration was completed with an all-ceramic crown. Follow-up 18 months after treatment revealed good periodontal health, esthetics and normal function.

© 2017 Association for Dental Sciences of the Republic of China. Publishing services by Elsevier B.V. This is an open access article under the CC BY-NC-ND license (<http://creativecommons.org/licenses/by-nc-nd/4.0/>).

## Introduction

Crown-root fractures comprise 5% of injuries affecting the permanent dentition and are usually caused by direct

trauma to the anterior teeth. These dental injuries extend below the cemento-enamel junction and involve enamel, dentine, and cementum, with or without pulpal involvement.<sup>1</sup>

\* Corresponding author. Department of Prosthodontics, Faculty of Dentistry, İstanbul Aydın University, 34180 Bahçelievler, İstanbul, Turkey.  
E-mail address: [ahmetguler@aydin.edu.tr](mailto:ahmetguler@aydin.edu.tr) (A.U. Güler).

<http://dx.doi.org/10.1016/j.jds.2012.09.019>

1991-7902/© 2017 Association for Dental Sciences of the Republic of China. Publishing services by Elsevier B.V. This is an open access article under the CC BY-NC-ND license (<http://creativecommons.org/licenses/by-nc-nd/4.0/>).

The treatment strategy for a crown-root fracture is complex and providing an esthetic result is an important criterion of success.<sup>2</sup> The literature reports several different treatments for crown-root fractures: fragment removal and restoration<sup>3</sup>; gingivectomy and osteotomy (crown lengthening)<sup>1,3,4</sup>; orthodontic extrusion with/without gingivoplasty<sup>1,3-7</sup>; surgical extrusion<sup>1,3,4,8</sup>; vital root submergence<sup>3,9</sup>; and extraction followed by surgical implants<sup>3,4</sup> or fixed partial dentures.<sup>10</sup> The choice of treatment depends on the extent of the subgingival lesion, the morphology of the lesion, the length and the morphology of the root, and the appearance in this esthetically sensitive region.<sup>3</sup>

Orthodontic extrusion is a conservative procedure according to extraction that allows retention of a tooth without the disadvantages of fixed partial dentures, and it does not involve loss of bone or periodontal support. Moreover, crown-lengthening techniques involve additional resection of bone or periodontal tissues and cause reduction of residual bone support.<sup>11</sup> Orthodontic root extrusion alters the relation between a nonrestorable tooth and its attachment apparatus, by elevating sound tooth material within the alveolar socket. Extrusion of such teeth raises the fracture line above the epithelial attachment so the proper finishing margins can be prepared.<sup>7</sup>

This case report describes a multidisciplinary approach using orthodontic forced eruption to facilitate the prosthetic restoration of a subgingivally fractured maxillary permanent central incisor.

## Case presentation

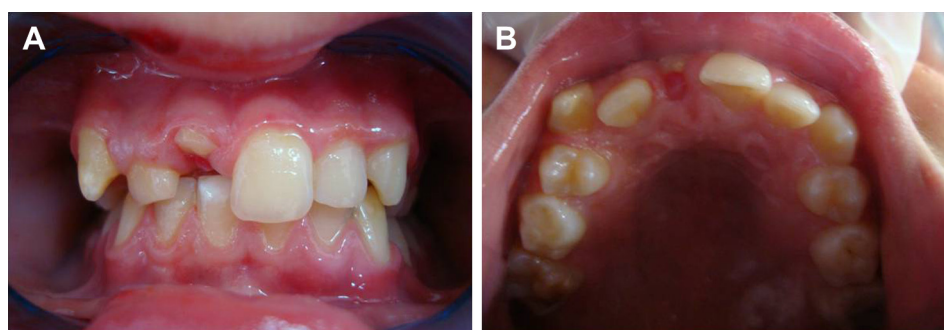
A 14-year-old male patient presented at the pediatric dental clinic due to unesthetic appearance and for management of fractured maxillary right central incisor tooth. His medical history was noncontributory. He had reportedly had a schoolyard accident some 48 hours prior to his attendance. The general dental practitioner carried out clinical and radiographical examination but performed no treatment before referring the child to our clinic.

Intraoral examination revealed that the maxillary right central incisor sustained an oblique crown-root fracture with pulp exposure. The fracture line extended below the gingival level at the palatal surface of the tooth. The missing tooth fragment had been left at the accident site.

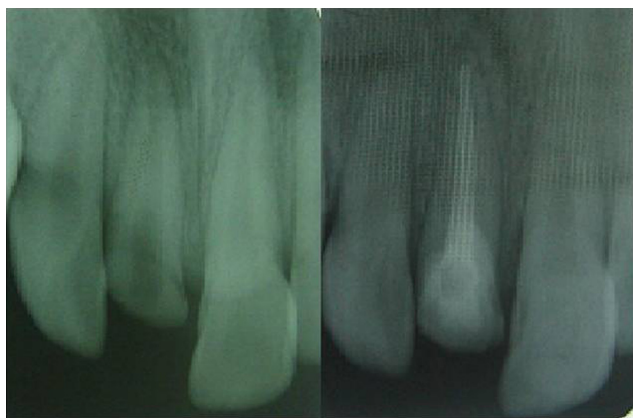The adjacent teeth showed no sign of mobility, and electric pulp responses gave positive readings (Fig. 1). Periapical radiographs taken from different angles revealed an oblique crown-root fracture. Also, the absence of radiographic findings in the neighboring teeth confirmed the clinical diagnosis.

We decided to initiate orthodontic extrusion of the traumatically injured root to facilitate placement of a coronal restoration. The patient and his mother were informed about the advantages and possible complications of the treatment plan. Even though a full arch orthodontic treatment had been decided to solve confusion about orthodontic extrusion, this approach was eventually rejected by the patient for social and economical reasons. After the patient and his parents approved the orthodontic extrusion, electrosurgery was used to re-establish the gingival margin and to convert the subgingival fracture site to a supragingival site. The pulpal tissue was then extirpated and calcium hydroxide paste applied following preparation and cleaning of the root canal. The exposed root cavity was filled with glass-ionomer cement (Fuji IX; GC Corporation, Tokyo, Japan) to prevent the new gingival margin. On a subsequent visit, we then obturated the canal with gutta-percha points and Sealapex (SybronEndo; Sybron Dental Specialties, Glendora, CA, USA; Fig. 2). Then, orthodontic root extrusion was performed with a modified Hawley appliance prior to prosthetic rehabilitation. After bending a hook with the shoulder at the level of the right central incisor, 3.2 mm medium elastic was used between the hook and a metal button bonded on the vestibule enamel surface of the right central incisor. In this way, an extrusive force of approximately 50 g was applied along the long axis of the tooth. The patient was told to use the appliance full time and to change the elastics once a day. In three months, 2 mm of extrusion was produced and application of force was ended. For retention, 3.2 mm light elastic was maintained for another 4 weeks (Fig. 3). The level of force was 10–20 g during this period. After extrusion was completed, the fracture level had risen 2 mm beyond the gingival margin (Fig. 4).

Following the orthodontic extrusion, proper fiber post was selected to restore the fractured tooth. The gutta-percha was partially removed leaving the apical 4 mm of the filling to maintain a good seal. A post hole was prepared within the root and coronal fragment using a drill. A glass fiber post (Cytec blanco glass fiber; Hahnenkratt,



**Figure 1** (A) Frontal view of fractured maxillary right central incisor. (B) Occlusal view of fractured maxillary right central incisor.

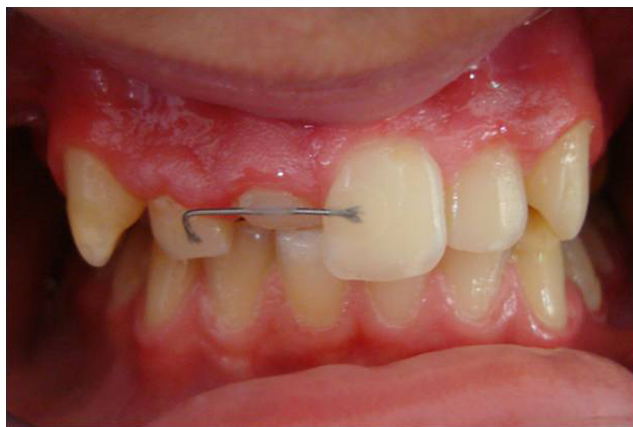

**Figure 2** Radiographic view of fractured tooth before and after endodontic treatment.

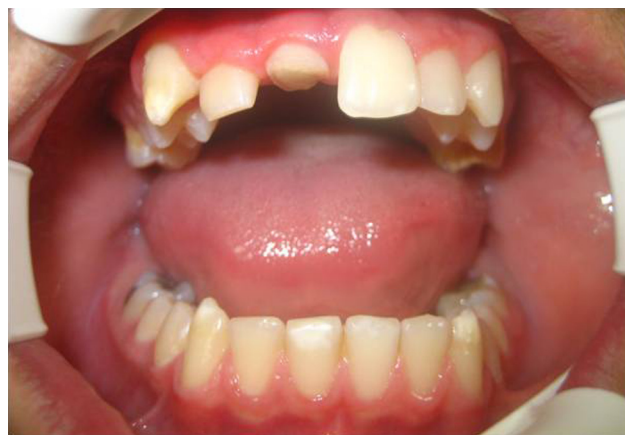Königsbach-Stein, Germany) cemented within the root canal using dual adhesive cement (Panavia F2.0; Kuraray Medical Inc., Tokyo, Japan). The post was covered with flowable composite (Aelite Flo; Bisco, Inc., Schaumburg, IL, USA; Fig. 5). Tooth preparation was performed with a circumferential shoulder margin configuration and a ferrule was set up to increase the fracture resistance of the remaining tooth structure and the retention of the prosthesis (Fig. 6).

Impressions were made with vinyl polysiloxane impression material (Elite H-D; Zhermack, Badia Polesine, Italy) using fabricated trays. The analog with zirconium core was prepared and (T Rigid; Zirkozahn GmbH, Gais, Italy) examined in the mouth. After that the core was fabricated using an analog system (ICE Zirkon; Zirkozahn). Veneering porcelain was used to complete the all-ceramic crown. The marginal fit and occlusion of the crown intraorally were evaluated, and it was then glazed and cemented with dual-polymerizing resin cement (Panavia F2.0; Kuraray Medical Inc; Fig. 7).

After 18 months, clinical and radiographic examination showed good esthetic results and periodontal health. No relapse occurred during the follow-up period, and the tooth showed no signs of root resorption.



**Figure 3** Extruded tooth was retained with arc wire for 4 weeks to prevent any relapse.

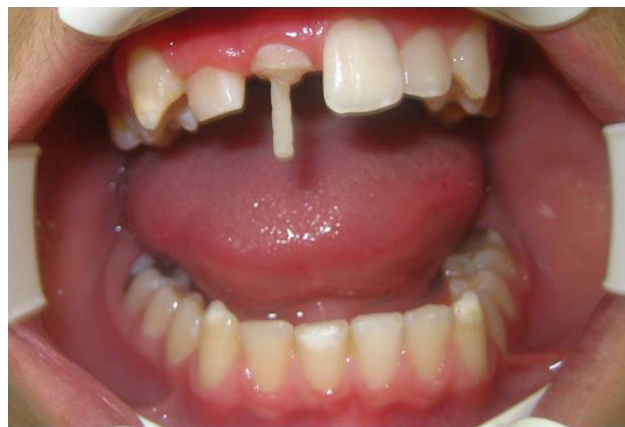

**Figure 4** Fracture level rising 2 mm over the gingival margin with 8 weeks of orthodontic treatment.

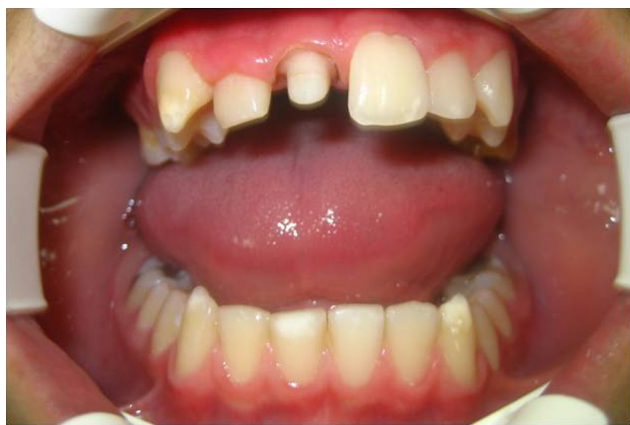## Discussion

Subgingivally-fractured young permanent teeth in the anterior region present a restorative challenge for the clinician. The method of treating these teeth is to expose the fractured margins, so that all clinical procedures can be managed with strict moisture and bleeding control. The prognosis may further improve through better plaque control by the patient.<sup>2</sup> This type of treatment usually implies a multidisciplinary approach.<sup>3</sup> This case report presents successful multidisciplinary treatment of a subgingivally-fractured tooth requiring cooperation of pedodontists, prosthodontists, and an orthodontist.

A number of treatment options have been proposed for crown-root fractures, each with their own advantages and disadvantages.<sup>1-6,8-10</sup> Extraction should not be the first choice of treatment for a fractured or extremely broken young permanent tooth in the anterior area,<sup>7</sup> because it leads to loss of bone in the area, compromising future treatment with implants.<sup>1,3</sup> In this case, if extraction were performed, an uncomfortable removable appliance would have to be worn until the patient is 18-years-old. The associated potential for plaque retention increased the



**Figure 5** Fiber post at adequate dimension was placed into the fractured tooth.

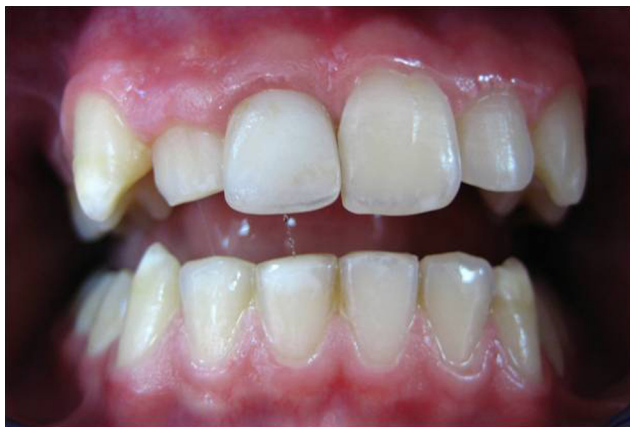

**Figure 6** Resin core built and tooth prepared with a circumferential shoulder margin configuration.

caries risk of adjacent teeth.<sup>5</sup> To avoid these problems, we had to consider alternative treatment modalities.

One of the alternative approaches to extraction of the tooth is vital tooth submergence, in which the root fragment is retained *in situ* in order to preserve alveolar bone until the root can be replaced by an implant.<sup>3,9</sup> The other treatment alternatives include osteotomy, gingivectomy, and surgical or orthodontic extrusion of the root.<sup>1,3–8</sup> Crown lengthening procedures can be employed to prevent inconsistent bone levels and resulting periodontal complications. This approach may require surgical intervention including the adjacent teeth<sup>12,13</sup> and produces a severe esthetic problem in the anterior area. Therefore this treatment option should be reserved for the posterior region, for shallower fractures, or for patients needing only palatal gingivectomy and osteotomy.<sup>7</sup>

Surgical extrusion is a one-step procedure that is simpler and less time-consuming, requiring minimal commitment from the patient.<sup>1,3,8</sup> The main drawback to this procedure is the possible risk of root resorption because of damage of the periodontal ligament.<sup>1,3</sup> Considering the disadvantages of the other methods mentioned above, we chose orthodontic extrusion to expose the fracture line before restoration in the case reported here.



**Figure 7** Frontal view of the fractured tooth after treatment.

An orthodontic approach allows the movement of the fracture line supragingivally and then optimizes the marginal sealing without risking the esthetic appearance.<sup>7</sup> Orthodontic extrusion of a fractured tooth will maintain the periodontal tissues at the same level and restore a physiological attachment,<sup>14</sup> leaving 3–4 mm distance from the alveolar crest to the coronal extension of the remaining tooth.<sup>15</sup> In the present case, 2–3 mm of forced eruption were obtained within 8 weeks. Then the extruded tooth was retained with arc wire for 4 weeks to prevent any relapse. In general, 3–6 weeks of stabilization should be sufficient after extrusion.<sup>16</sup> The open space in the apical region consists partly of uncalcified osteoid, which is not perceptible on a radiograph. After 4–5 weeks, calcified bone starts to become visible in the apical area.<sup>17</sup>

When deciding on orthodontic extrusion and restoration with prosthetic rehabilitation, some confounding factors must be taken into account, such as crown–root ratio, root abnormalities, fracture type and location, interocclusal space, and risk of exposure of furcation of a multi-rooted tooth.<sup>11,18</sup> The major limitation of this approach is that it increases the duration of treatment and requires a longer stabilization period.<sup>15</sup> Also, orthodontic devices may cause esthetic problems, affect oral hygiene and may be discouraging for some patients.<sup>19,20</sup> Rapid orthodontic extrusion involves stretching the periodontal fibers without any marked bone remodeling and can cause discrepancy between adjacent gingival levels.<sup>21</sup> Conservative periodontal surgery (gingivectomy, gingivoplasty), along with gingival recontouring to correct any discrepancy, may be necessary after rapid extrusion.<sup>22</sup> When stronger forces are exerted, as in rapid extrusion, bone and periodontal tissue movement is less pronounced because the rapid movement exceeds their physiologic adaptation capacity. In the normal course of events, bone and gingival movement is produced through low-intensity extrusive force, as in this case. In this case, the orthodontic extrusion procedure allowed the movement of the fracture line supragingivally, along with bone remodeling and gingival margin displacements.<sup>11</sup>

At the end of the orthodontic extrusion procedure, there was some discrepancy between the gingival margin level of the treated tooth and the adjacent teeth. Periodontal surgical crown lengthening techniques alone were not enough to get appropriate results, and reduction of the residual bone with osteotomy could further reduce the bone support. Bone reconstruction would cause root resorption. Another limitation to obtain better esthetic results is related to the anatomic structure of the roots. The mesiodistal diameter of the root, which is naturally “strangled” at the cemento-enamel junction of single-root teeth, is reduced with progression of the extrusion (especially in conical roots), which involves expansion of interproximal gingival embrasures.<sup>11,23</sup> Finally the use of a glass fiber post and all-ceramic crown provides good esthetic results and increases retention, distributing stress along the root.

A key factor in successful functional and esthetic rehabilitation of a crown-root fracture is use of a multidisciplinary approach that involves pedodontics, orthodontics, periodontics, and prosthodontics. In this case, a subgingivally fractured central incisor was treated endodontically, extruded and restored with a fiber post and full ceramic crown.

## References

1. Andreasen JO, Andreasen FM, Tsukiboshi M. Crown-root fractures. In: Andreasen JO, Andreasen FM, Andersson L, eds. *Textbook and Color Atlas of Traumatic Injuries to the Teeth*. Copenhagen: Blackwell Munksgaard, 2007:314–36.
2. Poi WR, Cardoso Lde C, de Castro JC, Cintra LT, Gulinelli JL, de Lazari JA. Multidisciplinary treatment approach for crown fracture and crown-root fracture—a case report. *Dent Traumatol* 2007;23:51–5.
3. Olsburgh S, Jacoby T, Krejci I. Crown fracture in the permanent dentition: pulpal and restorative considerations. *Dent Traumatol* 2002;18:103–15.
4. Villat C, Machtou P, Naulin-Ifi C. Multidisciplinary approach to the immediate esthetic repair and long-term treatment of an oblique crown-root fracture. *Dent Traumatol* 2004;20:56–60.
5. Zyskind K, Zyskind D, Soskolne WA, Harary D. Orthodontic forced eruption: case report of an alternative treatment for subgingivally fractured young permanent incisors. *Quintessence Int* 1992;23:393–9.
6. Yüzügülü B, Polat O, Ungör M. Multidisciplinary approach to traumatized teeth: a case report. *Dent Traumatol* 2008;24:e27–30.
7. Koyuturk AE, Malkoc S. Orthodontic extrusion of subgingivally fractured incisor before restoration. A case report: 3-years follow-up. *Dent Traumatol* 2005;21:174–8.
8. Çalışkan MK, Türkün M, Gomel M. Surgical extrusion of crown-root-fractured teeth: a clinical review. *Int Endod J* 1999;32:146–51.
9. Mackie IC, Quayle AA. Alternative management of a crown root fractured tooth in a child. *Br Dent J* 1992;173:60–2.
10. Meiers JC, Freilich MA. Chairside prefabricated fiber-reinforced resin composite fixed partial dentures. *Quintessence Int* 2001;32:99–104.
11. Bach N, Baylard JF, Voyer R. Orthodontic extrusion: periodontal considerations and applications. *J Can Dent Assoc* 2004;70:775–80.
12. Heithersay GS. Combined endodontic-orthodontic treatment of transverse root fractures in the region of the alveolar crest. *Oral Surg Oral Med Oral Pathol* 1973;36:404–15.
13. Ingber JS. Forced eruption. Part II. A method of treating non-restorable teeth: periodontal and restorative considerations. *J Periodontol* 1976;7:203–16.
14. Heda CB, Heda AA, Kulkarni SS. A multi-disciplinary approach in the management of a traumatized tooth with complicated crown-root fracture: a case report. *J Indian Soc Pedod Prev Dent* 2006;24:197–200.
15. Kocadereli I, Taşman F, Güner SB. Combined endodontic-orthodontic and prosthodontic treatment of fractured teeth. Case report. *Aust Dent J* 1998;43:28–31.
16. Proffit WR, Fields HW, David MS. *Contemporary Orthodontics*. St Louis: Elsevier Mosby, 2000:630.
17. Graber T, Vanarsdall R, Vig K. *Orthodontics: Current Principles & Techniques*. St Louis: Elsevier Mosby, 2005:181.
18. Shillingburg HT. *Fundamentals of Fixed Prosthodontics*, 3rd ed. Carol Stream, IL: Quintessence Publishing, 1999.
19. Mantzikos T, Shamus I. Case report: forced eruption and implant site development. *Angle Orthod* 1998;68:179–86.
20. Minsk L. Orthodontic tooth extrusion as an adjunct to periodontal therapy. *Compend Contin Educ Dent* 2000;21:768–70. 772, 774.
21. Heithersay GS, Moule AJ. Anterior subgingival fractures: a review of treatment alternatives. *Aust Dent J* 1982;27:368–76.
22. Malmgren O, Malmgren B, Frykholm A. Rapid orthodontic extrusion of crown root and cervical root fractured teeth. *Endod Dent Traumatol* 1991;7:49–54.
23. Cronin RJ, Wardle WL. Prosthodontic management of vertical root extrusion. *J Prosthet Dent* 1981;46:498–504.