



ORIGINAL ARTICLE

Vascular endothelial growth factor and biphasic calcium phosphate in the endosseous healing of femoral defects: An experimental rat study



Elçin Bedeloğlu^a, Selim Ersanlı^b, Volkan Arısan^{b*}

^a Department of Oral and Maxillofacial Surgery, Faculty of Dentistry, Istanbul Aydın University, Istanbul, Turkey

^b Department of Oral Implantology, Faculty of Dentistry, Capa, Istanbul University, Istanbul, Turkey

Received 10 December 2015; Final revision received 27 April 2016

Available online 9 July 2016

KEYWORDS

bone regeneration;
calcium phosphate;
histology;
histomorphometry;
rat;
vascular endothelial
growth factor

Abstract *Background/purpose:* The presence of adequate bone volume is a critical factor in rehabilitative dentistry. Despite the use of many promising alloplasts, success in stimulating bone formation has been limited, mostly due to poor local biological response. Growth factors have been introduced to stimulate angiogenesis and new bone formation. This histologic and histomorphometric study aimed to evaluate the effect of vascular endothelial growth factor (VEGF) and a biphasic alloplastic graft material (BA) on the healing of endosseous defects in rats.

Materials and methods: Twenty male Wistar rats were used. Two critical-sized bone defects were created in both the right and left femurs of each rat. Each defect was randomly assigned to be treated with VEGF, BA, or VEGF + BA, or to be left empty as a control. Half of the animals were sacrificed after 1 week, and the remaining half were sacrificed after 2 weeks. Inflammation, necrosis, and new bone areas were evaluated by means of histologic and histomorphometric analyses. *Results:* Compared to the control group, defects treated with VEGF alone or in combination with BA showed higher rates of bone formation (33.10–46.60%) on Day 7. Additionally, VEGF significantly reduced inflammation and necrosis ($P < 0.001$). However, the differences were no longer discernable on Day 14.

Conclusion: VEGF makes a significant contribution to angiogenesis and osteogenesis in the early stages of bone defect healing, and its combination with an osteoconductive grafting material (BA) may further enhance new bone formation.

© 2017 Association for Dental Sciences of the Republic of China. Publishing services by Elsevier B.V. This is an open access article under the CC BY-NC-ND license (<http://creativecommons.org/licenses/by-nc-nd/4.0/>).

* Corresponding author. Dr. Volkan Arısan, Department of Oral Implantology, Faculty of Dentistry, Istanbul University, 34390-Capa, Istanbul, Turkey

E-mail address: varisan@istanbul.edu.tr (V. Arısan).

<http://dx.doi.org/10.1016/j.jds.2016.04.005>

1991-7902/© 2017 Association for Dental Sciences of the Republic of China. Publishing services by Elsevier B.V. This is an open access article under the CC BY-NC-ND license (<http://creativecommons.org/licenses/by-nc-nd/4.0/>).

Introduction

Bone defects caused by periodontal disease, trauma, congenital anomalies, infection, and malignancies pose a serious problem in dentistry.¹ Despite various treatment methods and proposed grafting materials, no treatment is available to regenerate bone defects reliably.² Autogenous grafts have been used with a high success rate. However, they create a second wound area and postoperative morbidity.³ Furthermore, surface bone resorption was evident in long-term follow-up studies.⁴ Allogenic and alloplastic grafting materials represent a more conservative approach, but they lack osseointegrative properties because of the strict decontamination and sterilization procedures involved in their production.⁵ Growth factors have been used as an adjunct to these materials in stimulating new bone formation. This combination is intended to establish a beneficial healing environment and to recreate the former structural integrity of the defective area in a cost-effective and minimally invasive manner.⁶ Among these materials, biphasic calcium phosphates constitute a promising alternative by its space-maintaining and regenerative properties in the bone tissue.^{5,6}

When alloplasts are used alone, their osteoinductive characteristics have been shown to be insufficient for bone defect repair, perhaps because they fail to elicit sufficient vital nutrient spread in the bulk graft body.⁷ Concurrent use of various growth factors has yielded better outcomes by triggering cellular differentiation and migration within the alloplast body.^{8,9} Bone replacement via alloplast needs to be accompanied by ample vascularization because osteoid deposition and turnover depends on several different cell groups and phases.¹⁰ Vascularization is thus one of the most important prerequisites for bone healing.¹¹ In previous work, vascular endothelial growth factor (VEGF) has been shown to stimulate local vascular regeneration in bone healing.¹² Moreover, it has been demonstrated that VEGF plays an important role in new bone formation by enhancing chemotaxis of mesenchymal stem cells and by stimulating differentiation and proliferation of osteoblasts via an indirect effect on osteoprogenitor cells.¹³ VEGF is produced by various types of cells, including tumor cells, macrophages, platelets, keratinocytes, and renal mesenchymal cells.¹⁴ The functions of VEGF are not limited to the vascular endothelial system.¹⁵ It has been stated that VEGF also plays a role in normal physiological functions such as bone formation, hematopoiesis, and wound healing.¹⁶ Angiogenesis plays an important role in endochondral ossification, the process by which avascular cartilage tissue becomes vascular bone tissue. During bone development, signals required for apoptosis of hypertrophic chondrocytes in epiphyseal growth plaques are provided by new blood vessels. Over the course of this process, VEGF is secreted from hypertrophic chondrocytes; thus, growth of metaphyseal vessels into cartilage tissue and new bone formation occurs.¹⁷ VEGF also has chemotactic effects on osteoblasts. It has been suggested that VEGF has a role in chondrocyte death, chondroclast function, extracellular matrix remodeling, angiogenesis, and regulation of bone formation.¹⁸ As a

consequence, VEGF plays an important role in both types of bone healing.

Enhanced healing properties provided by the VEGF may also improve osteogenesis and biodegradation of biphasic calcium phosphates. The aim of this histologic and histomorphometric study was to analyze the effect of VEGF and a biphasic alloplastic graft material (BA), when used alone or in combination on new bone formation in a rat model.

Materials and methods

Male Wistar rats ($n = 20$) aged 6–8 months and weighing between 350 g and 400 g were used. Approval of the Istanbul University Experimental Animals Ethics Committee (Istanbul, Turkey; No. 2010/160, Date: November 04, 2012) was obtained, and all procedures were conducted in accordance with the Istanbul University ethical guidelines for the treatment and welfare of experimental animals. The surgical procedure was performed by a surgeon (E.B.) licensed to work with experimental animals, and standard surgical techniques were used. General anesthesia was administered using a mixture of 40 mg/kg ketamine-HCl (Alfamine IM, Alfasan International B.V., Woerden, The Netherlands) and 5 mg/kg xylazine HCl (Alfazyne 2% IM, Alfasan International B.V.). Animals were fixed in standard posture, and the distal surface of their right and left femurs was shaved and disinfected with 70% alcohol solution. To reach the distal surface of the femur, 15–20 mm skin and subcutaneous tissue dissection was performed parallel to the long axis using a No. 15 scalpel. Two standard bone defects with a diameter of 3 mm were created using round drills (Gebr. Brasseler GmbH & Co. KG., Lemgo, Germany) in both the right and left femur of each experimental subject under physiological serum irrigation. The 3×3 critical-sized defect was based on a previous study.¹⁹

VEGF 165, which had been isolated from rat blood at the Experimental Medicine Research Institute (EMRI, Istanbul University), was stored in sterile tubes in cold chain and then brought to room temperature before use. Briefly, pcDNA3.1 plasmids were cloned and subjected to an electro-transfer procedure. Then, a toxin-free plasmid was produced, and the final VEGF plasmid was synthesized in a cell culture.

Using a predefined random order, each rat's four defects were filled with the following: (1) BA with a granule size of 500–1000 μm and a porosity of 90% (Bone Ceramic; Straumann, Basel, Switzerland; BA group); (2) VEGF alone; (3) VEGF and BA in combination (VEGF + BA group); or (4) nothing, which served as a control (Figure 1).

Following the application of the materials, flaps were repositioned with 3.0 silk sutures (Doğsan Medical, Trabzon, Turkey). Mild compression was applied to the surgical site using a gauze tampon. After the surgical procedure, a single dose of tetracycline (Tetra 10 mg/kg intramuscularly; Mustafa Nevzat İlaç Sanayii, İstanbul, Turkey) was administered to the experimental animals via the intraperitoneal route to prevent postoperative infection. All experimental animals were kept in metal cages in an automatized environment at $21 \pm 1^\circ\text{C}$, a relative humidity of 40–60% and 12-hour dark/light cycles until the sacrificing phase. Experimental animals were fed with tap water and standard pellets.

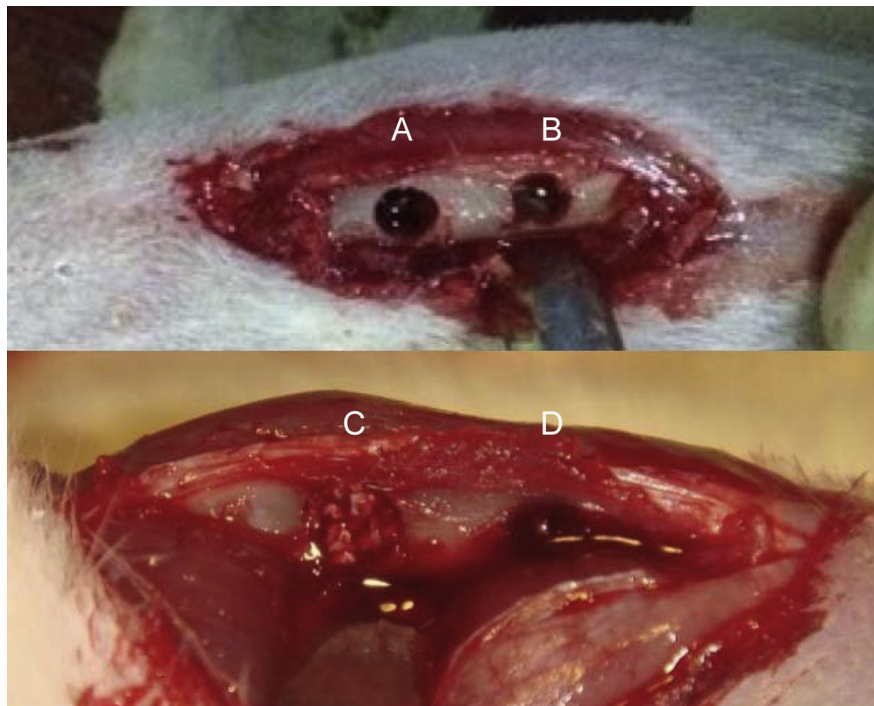


Figure 1 Visual appearance of the randomly allocated groups on the femoral defects: (A) VEGF group, (B) control group; (C) BA group, and (D) BA + VEGF group. BA = biphasic alloplastic graft material; VEGF = vascular endothelial growth factor.

Ten experimental animals were sacrificed at the end of the 7th day and 10 at the end of the 14th day by administering 135 mg/kg sodium pentothal via an intraperitoneal route. Previous studies have found that this timing maximizes the effectiveness of VEGF.¹⁹ Femur bones were separated from muscles with the help of a periosteum elevator and from joints with the help of a scalpel, and they were placed into a 10% formaldehyde solution and sent to a histology laboratory for histomorphometric examination.

Initially, materials were fixed with a 10% buffered formaldehyde solution for 48 hours. After fixation, a solution containing equal amounts of 50% formic acid and 20% sodium citrate was prepared, and the samples were decalcified for 3 days; they were then exposed to routine tissue tracing. Thereafter, 5–7- μ m sections were obtained from paraffin blocks, stained with hematoxylin and eosin, and examined under a light microscope.

During histomorphometric analysis, the following areas were measured using the Olympus Analysis Five (Olympus Corporation, Tokyo, Japan) image analysis program: newly formed bone tissue; fibrotic connective tissue, including the spaces resulting from loss of granulation tissue during demineralization; inflammatory cells; and necrotic tissue. The procedure was performed by measuring four separate areas for each of the criteria in four sections obtained from each block and by calculating a mean percentage according to total magnification area.

Data were analyzed using SPSS for Windows 15.0 (SPSS Inc., Chicago, IL, USA). Normality of the data distribution was checked using the Kolmogorov–Smirnov test. Inter-group comparisons of measures that were not normally distributed were performed using Kruskal–Wallis tests, whereas paired comparisons were performed using

Mann–Whitney *U* tests. Significance was evaluated at a level of $P < 0.05$. A Bonferroni correction was made on measurements derived from the same sample ($P < 0.0125$).

Results

Over the course of the healing period, no infection or complication was observed in any of the experimental animals. However, a fracture was detected in the defect area on the 2nd day of the healing period in one animal. This animal was replaced with another animal using the same protocol. Upon retrieval of the bone specimens, it was macroscopically observed that the integrity of the femur bones was preserved, and they showed no infectious reaction.

Histologic observation indicated that the graft particles were in direct contact with the host bone, with new bone growing into the graft-maintained area. This was more clearly seen in the samples from Day 14 than in those from Day 7. Bone deposition was evident at both time points. New bone tissue was integrated with fibrous tissue areas and residual graft particles, indicating graft resorption, in the VEGF and BA+ VEGF groups (Figures 2 and 3).

Histomorphometric analysis

Measured values of inflammation, necrosis, fibrosis and new bone formation areas of the groups on Day 7 and Day 14 are provided in Tables 1 and 2.

At both time intervals, inflammation and necrosis were significantly lower in the VEGF groups than in other groups (mean \pm SD, $19.4 \pm 11.16\%$ and $8.86 \pm 1.11\%$ inflammation; $P < 0.001$; $5.56 \pm 1.16\%$ and $1.01 \pm 0.86\%$ necrosis, $P < 0.001$

on Days 7 and 14, respectively). By contrast, the fibrosis measured in the VEGF group on Day 7 ($45.54 \pm 9.56\%$) was significantly higher than in other groups ($P < 0.001$). On Day 7, the rate of new bone formation was similar across the BA, VEGF and BA+ VEGF groups ($33.10 \pm 13.79\%$, $46.60 \pm 5.0\%$, and $43.40 \pm 8.00\%$, respectively) but was significantly lower in the control group ($16.2 \pm 3.42\%$, $P < 0.0001$). From Day 7 to Day 14, a statistically significant decrease in inflammation and necrosis was evident in all groups. Fibrosis and new bone formation showed a statistically significant increase on Day 14, except in the VEGF group. On Day 14, differences were no longer discernable between the groups. The highest new bone formation percentage was observed in the BA + VEGF group ($60.6 \pm 16.15\%$), but the differences were not significant (Figure 4).

Discussion

The regenerative effect of VEGF and BA applied to critical-sized defects in rat femurs was analyzed in this histologic and histomorphometric study. The treatment groups showed meaningful differences in bone formation and related healing variables (inflammation, necrosis, and fibrosis).

The primary goal of the augmentation method is to replace lost bone with living bone tissue so that modern rehabilitation treatments (such as osseointegrated implants or tissue-born prosthesis) can be undertaken. Therefore, any graft material placed into the lost bone volume needs to be vascularized internally to allow cellular infiltration

and bone cell migration. Especially in the oral cavity, this process is frequently hampered by poor soft tissue coverage and dehiscence, exposing the graft material to the oral cavity and resulting in complete loss of the grafting material or insufficient bone fill.²⁰ VEGF may actively contribute to this healing process by enhancing vascularization and soft tissue proliferation on the cellular level.²¹ The results of this study also showed that, when compared to a control group, early-term new bone formation can be enhanced by the use of VEGF.

Reis-Filho and colleagues²² extracted rat second molars and investigated the influence of a similar allograft on VEGF extraction. Maximum VEGF extraction was observed in the 1st week and 2nd week.²² Wang and colleagues conducted a controlled study in a rabbit model and created 15-mm critical-sized segmental defects in the femur, which were filled with autologous grafts, β -tricalcium phosphate (β -TCP), and vascular bundles. They stated that VEGF was effective in both angiogenesis and ossification, particularly in the first 3 weeks.²³ Kleinheinz et al²⁴ created a model of mandibular bicortical defects in 56 rabbits and divided them into two groups. In the first group, defects were left empty or were filled with type-I collagen, whereas the defects in the second group were filled with a collagen matrix and recombinant human VEGF. No significant difference was observed between the test and control groups in terms of new bone formation, but significantly higher bone density was observed in the test group.²⁴ To improve bone gain further, Yonamine and colleagues²⁵ placed a polylactic–glycolic acid membrane over calvarial defects treated with VEGF microspheres in rats. Radiological and

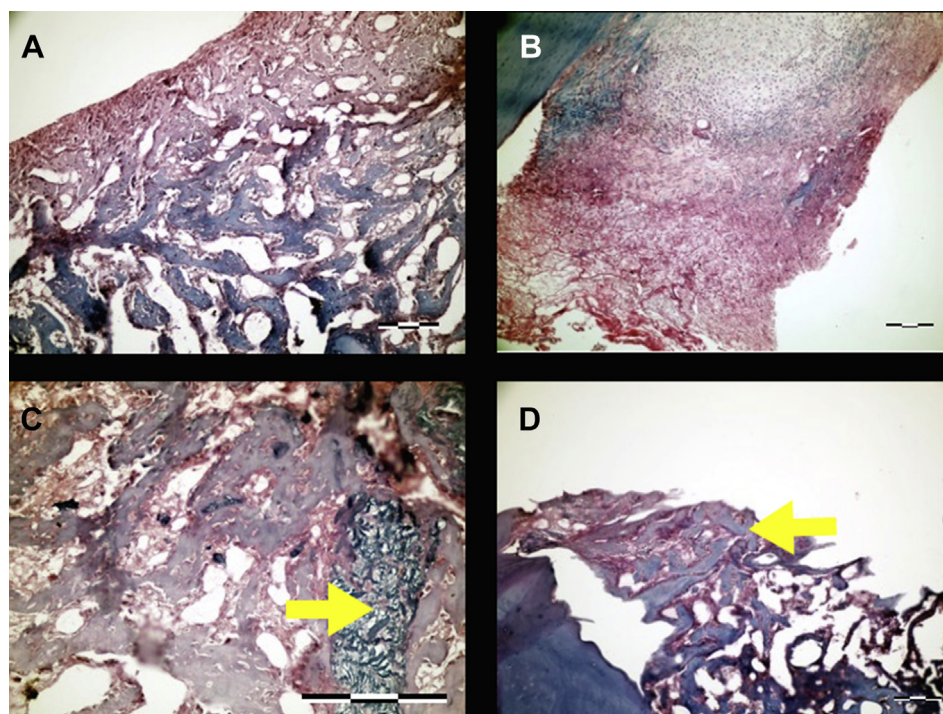


Figure 2 Histologic samples from animals that have healed for 1 week; hematoxylin and eosin staining: (A) large trabeculae are observed in the control defect; original magnification $\times 200$. (B) Chondral ossification is characterized with fibrosis tissue in the VEGF group; original magnification $\times 100$. (C) New bone deposition around the graft material (arrow) in the BA group; original magnification $\times 400$. (D) Active osteoid deposition on the graft material (arrow) in BA+ VEGF group; original magnification $\times 100$.

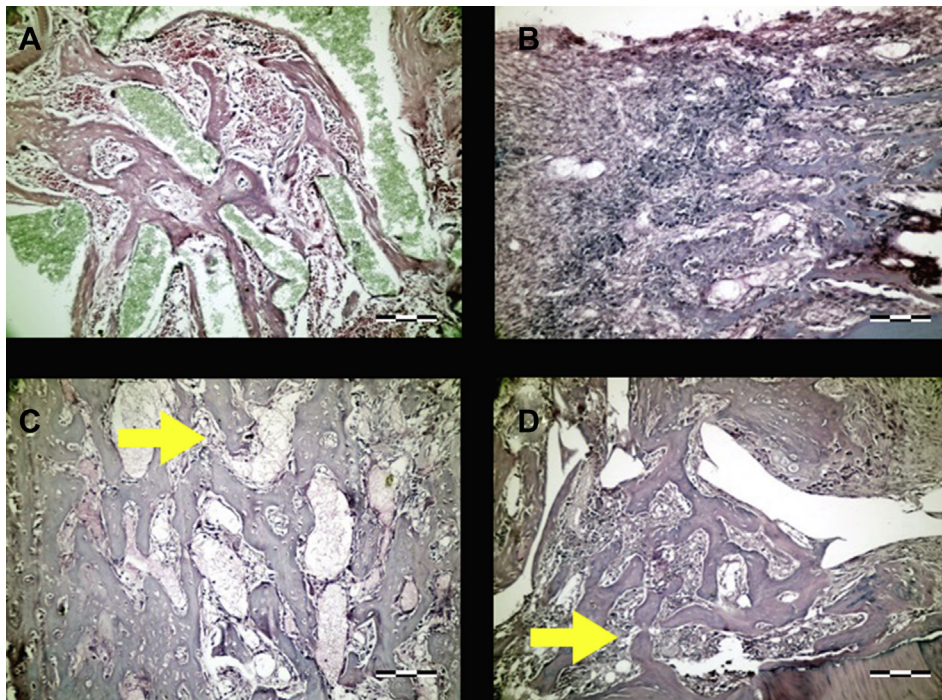


Figure 3 Histologic samples from animals that have healed for 2 weeks; hematoxylin and eosin staining. (A) Thick bone trabeculae surrounded by active connective tissue in the control group; original magnification $\times 200$. (B) New bone trabeculae in the defect region surrounded by numerous blood vessels; original magnification $\times 200$. (C) The graft material is surrounded by new bone deposition (arrow); original magnification $\times 200$. (D) Fibrotic tissues are being replaced by new bone tissue (arrow) surrounded by large blood vessels; original magnification $\times 200$.

Table 1 Inflammation, necrosis, fibrosis and new bone values at the 7th day.

	Day 7							
	Inflammation		Necrosis		Fibrosis		New bone	
	P < 0.001		P < 0.001		P < 0.001		P < 0.001	
Control	44.3 \pm 12.2 ^a	NS	21.1 \pm 10.2 ^e	NS	19.4 \pm 4.3 ⁱ	NS	16.2 \pm 3.4 ^m	n, o, p
BA	40.7 \pm 12.2 ^b	NS	21.1 \pm 9.5 ^f	NS	29.6 \pm 13.9 ^j	NS	33.1 \pm 13.7 ⁿ	NS
VEGF	29.2 \pm 15.0 ^c	a, b, d	21.1 \pm 9.5 ^g	e, f, h	46.1 \pm 6.2 ^k	i, j, l	46.6 \pm 5.0 ^o	NS
BA+ VEGF	40.6 \pm 11.2 ^d	NS	19.4 \pm 4.3 ^h	NS	25.9 \pm 13.8 ^l	NS	43.4 \pm 8.0 ^p	NS

Pairwise statistical comparisons of the mentioned variables are expressed as letters (a, b, c, and d for the inflammation variable; e, f, g, and h for the necrosis variable; i, j, k, and l for the fibrosis variable; and m, n, o, and p for the new bone variable in the control, BA, VEGF, and BA+ VEGF groups, respectively).

BA = biphasic alloplastic graft material; NS = not statistically significant; VEGF = vascular endothelial growth factor.

Table 2 Inflammation, necrosis, fibrosis, and new bone values at the 14th day.

	Day 14							
	Inflammation		Necrosis		Fibrosis		New bone	
	P < 0.001		P < 0.001		P < 0.001		P < 0.001	
Control	4.5 \pm 6.0	NS	1.4 \pm 2.9	NS	45.8 \pm 4.1	NS	46.3 \pm 5.0	NS
BA	9.7 \pm 2.7	NS	1.6 \pm 2.5	NS	38.1 \pm 11.4	NS	55.6 \pm 14.1	NS
VEGF	7.6 \pm 2.5	NS	0.9 \pm 1.9	NS	46.6 \pm 4.5	NS	53.9 \pm 13.3	NS
BA+ VEGF	12.6 \pm 7.8	NS	8.7 \pm 2.8	NS	40.1 \pm 7.6	NS	60.6 \pm 16.1	NS

BA = biphasic alloplastic graft material; NS = not statistically significant; VEGF = vascular endothelial growth factor.

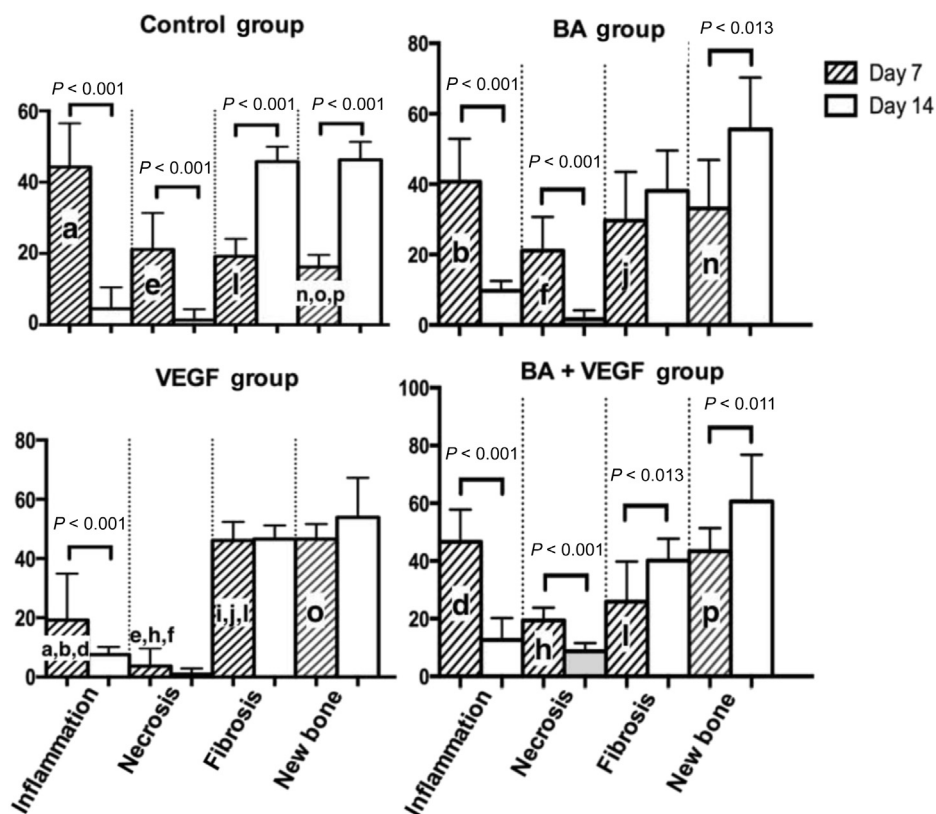


Figure 4 The rate of healing variables (inflammation, necrosis, and fibrosis and new bone formation) on Day 7 and Day 14. Pairwise statistical comparisons of the mentioned variables are expressed as letters for easy identification (a, b, c, and d for the inflammation variable; e, f, g, and h for the necrosis variable; i, j, k, and l for the fibrosis variable; and m, n, o, and p for the new bone variable in the control, BA, VEGF, and BA+ VEGF groups, respectively). BA = biphasic alloplastic graft material; VEGF = vascular endothelial growth factor.

histological evaluations revealed thick mature bone regeneration when VEGF was used in combination with a polylactic–glycolic acid membrane.²⁵ These results corroborate the outcomes of the present study, and it can be concluded that VEGF may enhance new bone formation at the very early stages of healing.

The time frame over which VEGF is effective was also investigated. It has been demonstrated that secretion of VEGF was limited to the early stages (1–3 weeks) of healing.^{26–28} Accordingly, the present study's sample retrieval schedule was employed to investigate the behavior of VEGF when combined with an alloplast (BA).

Such alloplasts (especially calcium phosphates) have been used widely because autologous grafts are difficult to obtain in sufficient quantity and can cause complications in the donor area. Alloplasts are inexpensive and lack the risk of disease transfer.^{29,30} Furthermore, they can be easily combined with various regeneration-inducing growth factors, including VEGF. This may be significant because alloplasts alone are only osteoconductive and frequently heal by stimulating surrounding tissue growth.²¹ The main core of alloplasts usually remains intact due to insufficient vascularization and reach of extracellular fluids.^{22,31}

Due to the disadvantages of HA alone, such as its fragile surface characteristics and irregular biodegradation, the use of β -TCP graft material in combination with HA has become widespread.^{9,32} The BA material used in the

present study consisted of a combination of HA and β -TCP at ratios of 60% and 40%, respectively. This combination has proven to be safe and optimal for bone defects such as extraction sockets, periodontal and peri-implant regeneration and endodontic surgery.^{6,33} It has been reported that this graft material acts like a skeleton for bone regeneration, does not interact with the physiological bone deposition process, and has high biocompatibility.^{2,34} Due to the amorphous nature and bulk application of these materials, complete bone replacement has not been achieved, especially in the middle region of the material.^{7,34,35} The present histologic observation suggests that the application of VEGF seems to increase vascular penetration and expedite bone replacement in the BA body. This approach may constitute a basis for the improvement of related alloplasts.

Within the limits of this study, it can be concluded that VEGF makes a significant contribution to recovery and osteogenesis in the early stages of bone defect healing, and its combination with an osteoconductive alloplast (BA) may further enhance new bone formation.

Conflicts of interest

The authors have no conflicts of interest relevant to this article.

Acknowledgments

The authors thank Dr. Sevda Özel (Department of Biostatistics and Bio-informatics, Faculty of Medicine, Istanbul University) for assistance with statistical analyses, Prof. Dr. Vakur Olgaç for the histologic analyses and Assoc. Prof. Dr. Duran Üstek (Department of Experimental Medicine, Faculty of Medicine, Istanbul University) for the synthesis of VEGF. This study was supported by a grant (BAP 20406 - 2012) from the Istanbul University Research Fund.

References

- Buckwalter JA, Einhorn TA, Simon SR, eds. *Orthopaedic Basic Science: The Biology and Biomechanics of the Musculoskeletal System*, 2nd ed. Chicago: Saunders, 2000:112–8.
- Lynch SE, Genco RJ, Marx RE, Spector M. Basic principles of tissue engineering. In: Lynch SE, ed. *Tissue Engineering: Applications in Maxillofacial Surgery and Periodontics*, 1st ed. Chicago: Quintessence Publishing, 1999:118–226.
- Parikh SN. Bone graft substitutes: past, present, future. *J Postgrad Med* 2002;48:142–8.
- Stevenson S, Emery SE, Goldberg VM. Factors affecting bone graft incorporation. *Clin Orthop Relat Res* 1996;324:66–74.
- Aichelmann-Reidy ME, Yukna RA. Bone replacement grafts. The bone substitutes. *Dent Clin North Am* 1998;42:491–503.
- Aloy-Prósper A, Maestre-Ferrin L, Peñarrocha-Oltra D, Peñarrocha-Diogo M. Bone regeneration using particulate grafts: an update. *Med Oral Patol Oral Cir Bucal* 2011;16:210–4.
- Arisan V, Ozdemir T, Anil A, Jansen JA, Ozer K. Injectable calcium phosphate cement as a bone-graft material around peri-implant dehiscence defects: a dog study. *Int J Oral Maxillofac Implants* 2008;23:1053–62.
- Rocha FS, Batista JD, Zanetta-Barbosa D, Dechichi P. Effect of different storage media on the regenerative potential of autogenous bone grafts: a histomorphometrical analysis in rabbits. *J Oral Implantol* 2013;39:635–42.
- Jimi E, Hirata S, Osawa K, Terashita M, Kitamura C, Fukushima H. The current and future therapies of bone regeneration to repair bone defects. *Int J Dent* 2012;2012:148–52.
- Giannoudis PV, Tzioupis C. Clinical applications of BMP-7: the UK perspective. *Injury* 2005;36:47–50.
- Hollinger JO, Buck CD, Bruder PS. Biology of bone healing: its impact on clinical therapy. In: Lynch SE, Genco RJ, Marx RE, eds. *Tissue Engineering: Applications in Maxillofacial Surgery and Periodontics*, 1st ed. Chicago: Quintessence Publishing, 1999:223–8.
- Giannobile WV. Periodontal tissue engineering by growth factors. *Bone* 1996;19:23–37.
- Keramaris NC, Calori GM, Nikolaou VS, Schemitsch EH, Giannoudis PV. Fracture vascularity and bone healing: a systematic review of the role of VEGF. *Injury* 2008;39:45–57.
- Chintalgattu V, Nair DM, Katwa LC. Cardiac myofibroblasts: a novel source of vascular endothelial growth factor (VEGF) and its receptors Flt-1 and KDR. *J Mol Cell Cardiol* 2003;35:277–86.
- Yancopoulos GD, Davis S, Gale NW, Rudge JS, Wiegand SJ, Holash J. Vascular-specific growth factors and blood vessel formation. *Nature* 2000;407:242–8.
- Gerber HP, Vu TH, Ryan AM, Kowalski J, Werb Z, Ferrara N. VEGF couples hypertrophic cartilage remodeling, ossification and angiogenesis during endochondral bone formation. *Nat Med* 1999;5:623–8.
- Fan BS, Lou JY. Enhancement of angiogenic effect of co-transfection human NGF and VEGF genes in rat bone marrow mesenchymal stem cells. *Gene* 2011;485:167–71.
- Bai Y, Li P, Yin G, et al. BMP-2, VEGF and bFGF synergistically promote the osteogenic differentiation of rat bone marrow-derived mesenchymal stem cells. *Biotechnol Lett* 2013;35:301–8.
- Havluclu U, Bolukbasi N, Yeniyl S, Cetin S, Ozdemir T. Effects of light-emitting diode photobiomodulation therapy and BioOss as single and combined treatment in an experimental model of bone defect healing in rats. *J Oral Implantol* 2015;41:110–7.
- Nevins M, Giannobile WV, McGuire MK, et al. Platelet-derived growth factor stimulates bone fill and rate of attachment level gain: results of a large multicenter randomized controlled trial. *J Periodontol* 2005;76:2205–15.
- Lynch SE, de Castilla GR, Williams RC, et al. The effects of short-term application of a combination of platelet-derived and insulin-like growth factors on periodontal wound healing. *J Periodontol* 1991;62:458–67.
- Reis-Filho CR, Silva ER, Martins AB, et al. Demineralised human dentine matrix stimulates the expression of VEGF and accelerates the bone repair in tooth sockets of rats. *Arch Oral Biol* 2012;57:469–76.
- Wang L, Pei GX, Gao LB, et al. Tissue engineering vascularized bone repairing segmental femoral bone defects in rabbits. *Zhonghua Yi Xue Za Zhi* 2010;15:1637–41.
- Kleinheinz J, Stratmann U, Joos U, Wiesmann HP. VEGF-activated angiogenesis during bone regeneration. *J Oral Maxillofac Surg* 2005;63:1310–6.
- Yonamine Y, Matsuyama T, Sonomura T, et al. Effectable application of vascular endothelial growth factor to critical sized rat calvaria defects. *Oral Surg Oral Med Oral Pathol Oral Radiol Endod* 2010;109:225–31.
- Eckardt H, Ding M, Lind M, Hansen ES, Christensen KS, Hvid I. Recombinant human vascular endothelial growth factor enhances bone healing in an experimental nonunion model. *J Bone Joint Surg Br* 2005;87:1434–8.
- Li R, Nauth A, Li C, Qamirani E, Atesok K, Schemitsch EH. Expression of VEGF gene isoforms in a rat segmental bone defect model treated with EPCs. *J Orthop Trauma* 2012;26:689–92.
- Lalani Z, Wong M, Brey EM, et al. Spatial and temporal localization of FGF-2 and VEGF in healing tooth extraction sockets in a rabbit model. *J Oral Maxillofac Surg* 2005;63:1500–8.
- Maiorana C, Redemagni M, Rabagliati M, Salina S. Treatment of maxillary ridge resorption by sinus augmentation with iliac cancellous bone, anorganic bovine bone, and endosseous implants: a clinical and histologic report. *Int J Oral Maxillofac Implants* 2000;15:873–8.
- Paul BF, Horning GM, Hellstein JW, Schafer DR. The osteoinductive potential of demineralized freeze-dried bone allograft in human non-orthotopic sites: a pilot study. *J Periodontol* 2001;72:1064–8.
- Al Subaie AE, Eimar H, Abdallah MN, et al. Anti-VEGFs hinder bone healing and implant osseointegration in rat tibiae. *J Clin Periodontol* 2015;42:688–96.
- Ryu HS, Youn HJ, Hong KS, Chang BS, Lee CK, Chung SS. An improvement in sintering property of beta-tricalcium phosphate by addition of calcium pyrophosphate. *Biomaterials* 2002;23:909–14.
- Suzuki T, Hukkanen M, Ohashi R, et al. Growth and adhesion of osteoblast-like cells derived from neonatal rat calvaria on calcium phosphate ceramics. *J Biosci Bioeng* 2000;89:18–26.
- Valentini P, Abensur D. Maxillary sinus floor elevation for implant placement with demineralized freeze-dried bone and bovine bone (Bio-Oss): a clinical study of 20 patients. *Int J Periodontics Restorative Den* 1997;17:232–41.
- Arisan V, Anil A, Wolke JG, Ozer K. The effect of injectable calcium phosphate cement on bone anchorage of titanium implants: an experimental feasibility study in dogs. *Int J Oral Maxillofac Surg* 2010;39:463–8.