




# Aydın Dental Journal

Journal homepage: <http://dergipark.ulakbim.gov.tr/adj>



## TREATMENT OF CHRONIC MUCOCELE IN LOWER LIP: A CASE REPORT

**DergiPark**  
AKADEMİK

*Saad Shahnawaz AHMED<sup>1</sup>, Hira ZAMAN<sup>2</sup>*

### ABSTRACT

Mucocele is a common benign cystic lesion of minor salivary glands consisting of two types: retention and extravasation. It mainly occurs due to trauma presenting anywhere in the oral cavity but main regions include the lip, the floor of the mouth or buccal mucosa. It has a higher incidence in lower lip in young patients with chronic trauma or parafunctional habits such as lip biting. This case presents a patient with growth on the lower lip which was tentatively diagnosed as mucocele based on the patient's history & clinical evaluation and histopathology confirmed our diagnosis. As mucocele is present in the general population so it is decided to review the clinical presentation and treatment options regarding mucocele that will aid in treatment planning in our daily clinical practice.

**Keywords:** *Benign lesion, parafunctional habits, minor salivary gland, oral mucocele, trauma.*

1 BDS, Islamic International Dental Hospital, Islamabad. <https://orcid.org/0000-0003-3778-1229>

2 BDS, MDS, Islamic International Dental Hospital, Islamabad. <https://orcid.org/0000-0001-6806-2679>

Correspondence: Saadahmed552@hotmail.com

**Received:** 17.08.2020 - **Accepted:** 07.09.2020

DOI: 10.17932/IAU.DENTAL.2015.009/dental\_v06i2003

## ALT DUDAKTA KRONİK MUKOSEL TEDAVİSİ: OLGU SUNUMU

### ÖZ

Mukosel, retansiyon ve ekstrasvazyon olmak üzere iki tipten oluşan minör tükürük bezlerinin sık görülen iyi huylu kistik lezyonudur. Esas olarak ağız boşluğunun herhangi bir yerinde görülen travma nedeniyle oluşur. En sık görüldüğü bölgeler dudak, ağız tabanı veya yanak mukozasını içerir. Kronik travmalı veya dudak ısırma gibi parafonksiyonel alışkanlıkları olan genç hastalarda alt dudakta görülme sıklığı daha yüksektir. Bu vaka, hastanın öyküsüne ve klinik değerlendirmesine dayanarak geçici olarak mukosel tanısı konulan ve histopatolojisi tanımımızı doğrulayan alt dudakta büyüme olan bir hastayı sunmaktadır. Genel popülasyonda mukosel mevcut olduğundan, günlük klinik pratiğimizde tedavi planlamasına yardımcı olacak mukosel ile ilgili klinik görünüm ve tedavi seçeneklerinin gözden geçirilmesi amaçlanmaktadır.

**Anahtar Kelimeler:** *Benign lezyon, parafonksiyonel alışkanlıklar, minör tükürük bezi, oral mukosel, travma.*

### INTRODUCTION

Mucocele is an accumulation of mucus secreted through salivary gland ducts in the oral cavity's subepithelial tissue which in turn causes limited swelling<sup>1, 2</sup>. It is listed as the 17<sup>th</sup> most common lesion of the oral cavity. Extravasation mucocele occurs due to the rupture of the duct leading to the accumulation of mucus around the surrounding soft tissue whereas retention mucocele occurs when there is a blockage of

the duct.<sup>3</sup>It can persist without increasing in size for months and has no sex predilection hence it can present in children, adolescents, and young adults. Clinically it presents as a round, bluish-colored, well-circumscribed lesion which is soft on palpation and is asymptomatic<sup>4, 5</sup>.

This case report discusses the excision of a mucocele in the lower lip.

### CASE REPORT

A 23-years-old female presented to the Dentistry Department, with the chief complaint of a growth on the right side of the lower lip intraorally which made her mastication difficult. The swelling had been for the past 3 months and the patient didn't recall any trauma to lip or lip biting habits. There was no significant medical history.

On clinical examination, a small swelling 1x1 cm was observed on the lower lip which was soft and painless as seen in fig [1]. Radiographic evaluation ruled out sialolithiasis. The lesion was diagnosed as mucocele based on clinical examination. Excision of the lesion was planned. Patient was explained the procedure and consultation taken.

Local anesthesia with 2% lignocaine (1:100000) was infiltrated in the lower lip. After achieving anesthesia at the excision site an elliptical incision was given and the lesion excised with a no.15 blade. Care was taken to make a smooth continuous incision and prevent the tearing of soft tissue. The lip is firmly pressed from both ends to prevent excessive bleeding and for a

clear surgical field, giving good visibility of the lesion. It is a good practice to excise some normal soft tissue all around the periphery of the lesion so that no tissue cells of the lesion are left behind which may cause it to reoccur. The site was then carefully examined and cleaned using saline irrigation. The margins of the incision were approximated and sutured using vicryl 4/0. Starting from the corners of elliptical excision first instead of the middle. Fig [2]. Analgesics (ibuprofen) and mouthwash (chlorhexidine) were prescribed. The patient's sutures were removed after 7 days. Follow up after every month was done and no occurrence was observed. Fig [3]

The specimen was sent for histopathology lab and diagnosed as extravasation Mucocele.

## DISCUSSION

Mucocele is a common lesion of the oral mucosa. It can arise from an alteration of minor salivary glands due to a mucous accumulation. They can present as vesicle or blister in the superficial mucosa filled with fluid or as a fluctuant nodule deep within the connective tissue<sup>6</sup>. The incidence of mucoceles is 2.5 lesions per 1000 patients, with no age predilection and occurs frequently in the second decade of life. It rarely occurs in children below 1 year of age<sup>7</sup>. Mucoceles of minor salivary gland that are superficial and are not greater than 1.5mm in diameter while deeper mucoceles are usually larger in diameter. The most common location is the lower lip especially in the premolar region as it is most prone to trauma followed by the tongue, buccal mucosa and palate<sup>8</sup>.

The two most common etiological factors of mucocele are traumatism and blockage

of salivary gland ducts. Retention mucocele prevalence in children is low due to the inability of ductal structure to contain an exaggerated accumulation of secretion. While extravasation mucocele is commonly found in children because extravasated saliva is first surrounded by inflammatory cells followed by granulation tissue composed mainly of fibroblast due to the absence of epithelial lining, this phenomenon is categorized as a pseudocyst or false cyst<sup>9</sup>.

The surface of long-standing lesions may show fibrosis<sup>10</sup>. Radiographic evaluation should also be done to rule out sialolithiasis<sup>11</sup>. The most commonly used treatment is surgical excision. A simple incision in the mucocele can be done to let the mucus drain but the mucocele would reappear when the wound heals. Other than excision with a blade, diode laser can also be used for excision since it is more beneficial as there is prompt hemostasis reduces surgical time, wound infection, and use of sutures isn't required. Other treatment options described by literature are cryosurgery, intralesional corticosteroid injection, micro marsupialization, marsupialization of the mucocele, conventional surgical removal of the lesion, and laser ablation<sup>12</sup>.

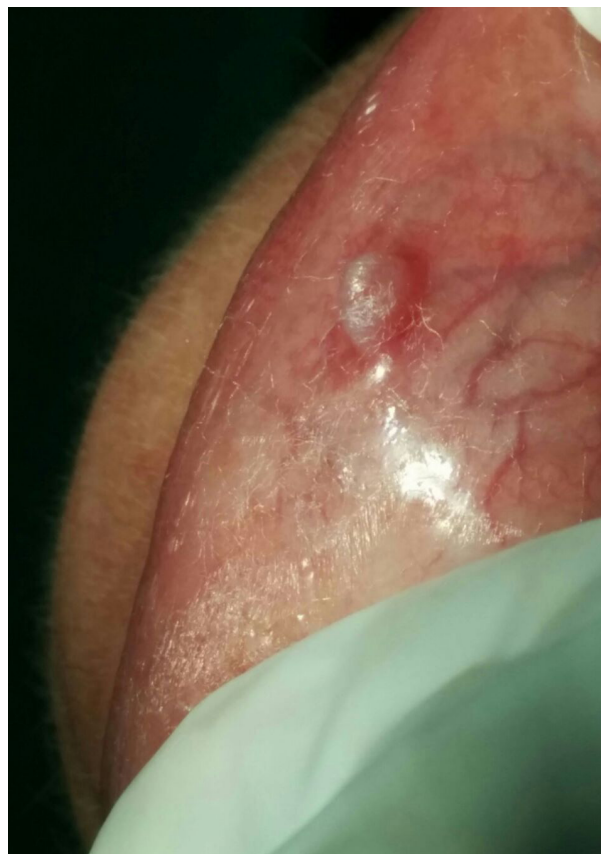## CONCLUSION

In summary, mucoceles are mostly benign asymptomatic extravasation or retention cystic lesions. These lesions present most often in the lower lip of young healthy patients due to chronic trauma or parafunctional habits like lip biting. A skillful operator should have sound knowledge of oral lesions, their clinical presentation along with associated signs and symptoms. This further leads to an accurate

diagnosis based on careful examination of patients' history, clinical examination, and radiographs. The lesion in this study presented as extravasation mucocele which was confirmed by the histopathologic test.

## REFERENCES

1. Baurmash HD. Mucoceles and ranulas. *J Oral Maxillofac Surg*, 2003; 61:369-78.
2. Bagan Sebastian JV, Silvestre Donat FJ, Penarrocha Diago M, Milian Masanet MA. Clinico-pathological study of oral mucoceles. *Av Odontoestomatol*, 1990;6:389-91, 394-5
3. Flaitz CM, Hicks JM. Mucocele and Ranula. eMedicine.2015. [Last cited on 2015 Feb 01]. Available from: <http://emedicine.medscape.com/article/1076717-clinical>
4. Boneu BF, Vidal HE, Maizcurrana TA, Gonzalez LJ. Submaxillary gland mucocele: presentation of a case. *Med Oral Patol Oral Cir Bucal*, 2005;10:180-4.
5. Eveson JW. Superficial mucoceles: Pitfall in clinical and microscopic diagnosis. *Oral Surg Oral Med Oral Pathol*. 1988;66:318–22. [[PubMed](#)]
6. Badjatia R, Badjatia S, Kulkarni V, Sharma D. Oral mucocele: a case report. *NJDSR*. 2014 Jan; 2(1)
7. Raj P, Malhotra R, Babaji P, Singh S. Oral mucocele: A case report. *Dental Impact*. 2014;6(1)
8. Ali J et al. Oral mucocele: a review of literature: *J Clin Exp Dent*. 2010; 2(1):e18-21.
9. Laller S, Saini R, Malik M, Jain R, An Appraisal of Oral Mucous Extravasation Cyst Case with Mini Review: case report: *JAMDSR*. 2014;2(2)
10. Mc Donald, Avery & Dean: *Dentistry for the child and adolescent*, Eight edition, Mosby, 2004.
11. Kumaresan R, Karthekeyan P, Muhammad F, Fairozekhan A. A Novel Technique for the Management of Blandin-Nuhn Mucocele: A Case Report. *IJCPD*. 2013;6(3):201-204.
12. Garcia J, Tost A, Ayets L, Escoda C. Treatment of oral mucocele- scalpel Vs CO2 laser. *Med Oral Patol Oral Cir Bucal*. 2009 Sep;1;14 (9):e469-74.



**Fig [1]** Pre-operative picture