




# Aydın Dental Journal

Journal homepage: <http://dergipark.ulakbim.gov.tr/adj>



## ***CLASS III MALOCCLUSION TREATMENT WITH MAXILLARY EXPANSION AND FACE MASK COMBINATION: A CASE REPORT***

**DergiPark**  
AKADEMİK

*Sanaz SADRY PhD DDS<sup>1</sup>, Muhammet GÜRCAN PhD DDS<sup>1</sup>, Nourtzan KECHAGIA DDS<sup>1</sup>*

### **ABSTRACT**

The aim of this case report is to present the treatment of a female patient with skeletal Class III malocclusion due to maxillary deficiency and negative overjet using a functional appliance. A 12-year 4-month old female patient applied for treatment to our clinic with a chief complaint of the position of her anterior teeth. The radiographic and clinical examinations and evaluations showed skeletal class III anomalies and absence of lateral maxillary incisor bilaterally. Initially, maxillary expansion was

provided to mobilize the maxillary sutures and then facemask was worn to improve the sagittal skeletal relation. Fixed orthodontic appliances were placed to align the dentition and Class III elastics were used to establish intercuspation and stability. A case with a skeletal class III malocclusion and negative overjet was treated in 2 years and 2 months in total, and class I canine relationship with normal overjet and good occlusion were achieved.

**Keywords:** *Class III anomaly, absence of lateral incisor, functional therapy*

<sup>1</sup> *Istanbul Aydın University Faculty of Dentistry Department of Orthodontics*

## **SINIF III MALOKLUZYONUN MAKSİLLER GENİŞLETME VE YÜZ MASKESİ KOMBİNASYONU İLE TEDAVİSİ: BİR VAKA RAPORU**

*Dr. Öğr. Üyesi Sanaz SADRY<sup>1</sup>, Dr. Dt. Muhammet GÜRÇAN<sup>1</sup>, Dt. Nourtzan KECHAGIA<sup>1</sup>*

### **ÖZ**

Bu vaka raporunun amacı, iskeletsel sınıf III malokluzyon ve negatif overjete sahip olan hastanın fonksiyonel aparey ve devamında sabit ortodontik tedavisini içeren olguyu sunmaktır. Kliniğimize kronolojik yaşı 12 yıl 4 ay olan kadın hasta, ön dişlerinin pozisyonunu beğenmemesi şikâyeti ile başvurdu. Yapılan klinik ve radyolojik değerlendirmede iskeletsel sınıf III anomali ve çift taraflı maksiller lateral diş eksikliği saptandı. İlk

olarak maksiller suturları mobilize etmek için Rapid Maksiller Ekspansiyon (RME) uygulandı ve sagittal ilişkiyi düzeltmek amaçlı facemask kullanıldı. Devamında sabit ortodontik tedavi ile dişsel düzelme sağlandı ve sınıf III elastikler ile interküspidasyon ve stabilite oluşturuldu. Toplam tedavi süresi 2 yıl 2 ay olan bu vakada sınıf I kanin ilişkisi normal overjet ve ideal bir okluzyon sağlandı.

**Anahtar Kelimeler:** *Sınıf III anomali, lateral diş eksikliği, fonksiyonel tedavi*

<sup>1</sup>*İstanbul Aydın Üniversitesi Diş Hekimliği Fakültesi Ortodonti ABD*

## INTRODUCTION

Facemask has been used in the early treatment of Class III patients with maxillary deficiency or mandibular prognathism (or both).<sup>1-4</sup> The potentially unfavorable growth pattern of the patients affected by this skeletal discrepancy, usually requires early and effective intervention.<sup>5</sup> One of the goals of the early treatment of Class III malocclusion with maxillary expansion and protraction headgear is to significantly improve the dentofacial profile. For these reasons, and because class III malocclusion is more often due to maxillary deficiency than mandibular excess, maxillary protraction may be the treatment choice for the majority of the cases.<sup>6</sup> Haas suggested the use of facemask in combination with Rapid Maxillary Expander (RME).<sup>7,8</sup> He reported that RME can produce a slightly forward movement of maxilla<sup>7,8</sup> and could weaken the circum-maxillary sutural forces, thereby facilitating the orthopedic effect of the facemask.<sup>7,8</sup> In 1966, Starnbach demonstrated that RME is able to promote the activity of surrounding maxillary sutures in non-human primates.<sup>9</sup> Baik et al.<sup>10</sup> found that the use of RME improves, in growing subjects, facemask efficacy. The purpose of this case report is to report the use of a rapid maxillary expansion for orthopedic facemask treatment in an adolescent patient with a developing Class III malocclusion.

## CASE REPORT

A 12 years and 4 months old female patient presented for initial examination at the clinic in good general health and no history of serious illness or injury. The chief complaint of the patient was related to the fact that she wasn't comfortable with the position of her anterior teeth. She had symmetrical face, competent lips, straight to concave profile,

an Angle Class I molar relationship for both sides, -2mm overjet and 4mm overbite, 2mm midline discrepancy of maxillary dental arch to right (Figure 1). The hand wrist radiograph showed that the patient was at peak skeletal stage (MP3cap) and panoramic radiograph showed that she has bilateral congenital absence of maxillary lateral incisors.

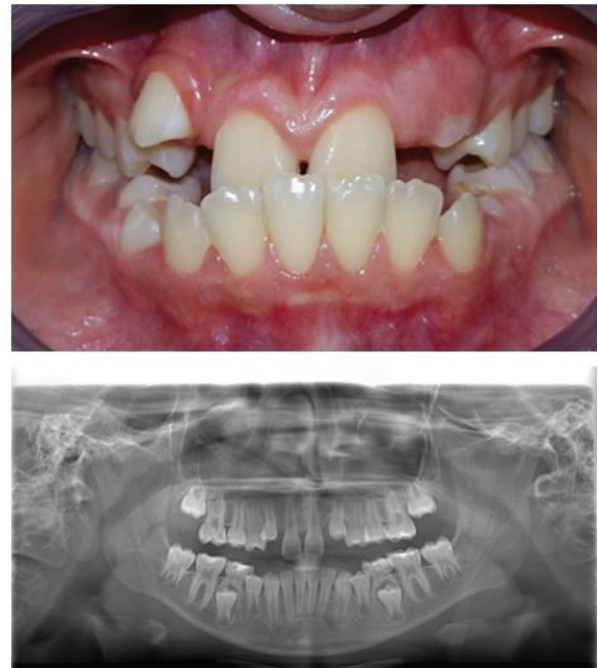

Figure 1: Initial intraoral photograph and panoramic radiograph

The side profile X-ray and cephalometric tracing showed: Class I skeletal pattern with maxillary and mandibular retrognathie according to Steiner analysis (SNA: 75.3°, SNB: 75°, ANB: 0.7°) skeletally Class III pattern with maxillar retrognathie and normal mandible according to McNamara analysis (Pn-A:-4mm, Pn-Pog:-7mm, Wits:-5mm), decreased effective mid-face dimension (Co-A: 71mm), slightly proclined upper incisors (U1-PP: 117°) and normal lower incisors, normal vertical growth pattern (SN-GoGn: 35°, FMA= 30°), normal positioned upper

and lower lip and increased nasolabial angle (NLA: 117°).

A treatment plan was established starting with a RME, and continued with a facemask. For the maximum efficiency of the facemask, RME was applied to activate maxillary sutures with the aim to stimulate the growth of the maxilla in the anterior direction and established the facial esthetics of the patient. Treatment was initiated by placing RME appliance with occlusal acrylic coverage and activated of 2/4 turn of the screw per day for two weeks. After the sutural activation of the maxilla, petit type facemask was used for the anterior protrusion of the maxillary complex with 400–500g of force and 5/16-inch elastics. The patient was advised to wear the facemask at least 14 hours each day (Figure 2). Excellent patient cooperation helped to attain the first stage of clinical treatment for 6 months. The SNA angle increased from 75.3 to 80.3 and the ANB angle increased from 0.3 to 5, while the wits appraisal decreased from -5mm to -1mm.

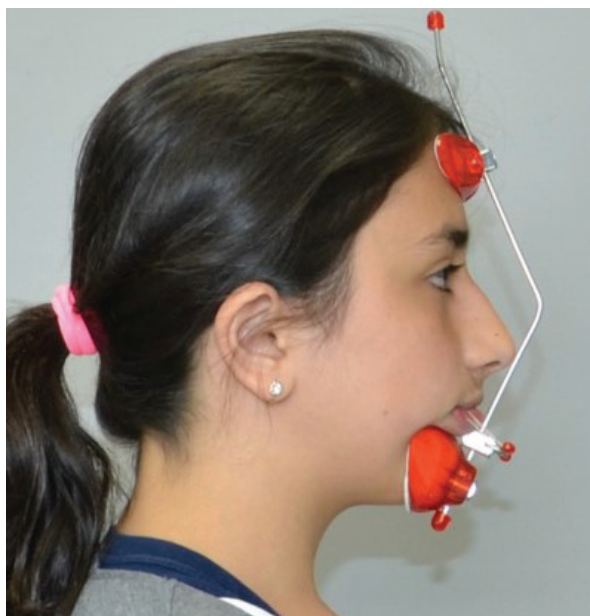


Figure 2: Petit type facemask

After the functional treatment, a fixed orthodontic treatment was started by applying 0.018 slot roth straight wire metal brackets to the lower and upper teeth. The orthodontic appliance was initially installed on the upper arch. An initial upper, Niti arc 0.014 was used. The sequence of upper Niti arches 0.016; 0.016 x 0.01; 0.016 x 0.022 was continued. It was only after adequate space and height had been achieved that the lower arch appliance was bonded. The same alignment and leveling procedures used for the upper arch were also performed on the lower dental arch, and to finish the case, a 0.019 x 0.025-in stainless steel archwire was used for both arches. Both jaws were passed to 0.016 x 0.022 stainless steel arches. After a short time, the overjet and overbite decreased, probably due to unanticipated mandibular growth although she had passed the age of peak velocity of height growth. Class I canine relationship were also achieved with class III elastics. After ensuring that all the intended goals had been achieved, the fixed orthodontic appliance was removed and the form of canine teeth was fixed and converted into a lateral tooth form. Fixed lingual retainers were bonded canine to canine on upper and lower arch and essix retainers were applied. Skeletally class III malocclusion with negative overjet was treated in the period of 2 years and 2 months, as a result of dental class II molar relationships due to the absence of lateral teeth, and class I canine relationship with normal overjet and good facial esthetics (Figure 3).

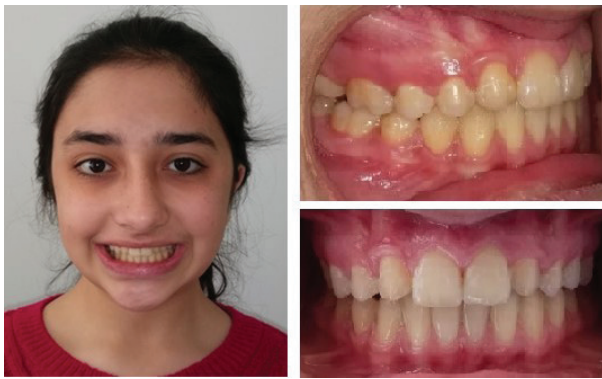

Figure 3: Final facial and intraoral photographs.

## DISCUSSION

The results obtained from the case report showed that facemask is an effective orthopedic approach to correct class III malocclusion. The application of an anteriorly directed force from a facemask to a RME appliance resulted in a significant improvement in midface esthetics (Table 1). This was noted by an increase in fullness of the infraorbital region and the correction of the skeletal discrepancy between the maxillary and mandibular jaw relationship (ANB from 0.3° to 2.7°, Wits from -5mm to -1mm) (Table 1). Since the maxilla articulates with nine other bones of the craniofacial complex, palatal expansion may disarticulate the maxilla and initiate cellular response in the sutures, allowing a more positive reaction to protraction forces<sup>9</sup>. It is, therefore, of interest to note that in the present case report, no transverse expansion was necessary to obtain a similar amount of displacement of the maxilla. In this case, comparison of pre-treatment and post-treatment lateral cephalogram showed that SNA increased from 75.3° to 79°. Co-A dimension increased from 71mm to 78mm,

retroclination of upper and lower incisors and protruded position of both upper and lower lip. The mesialization of upper molar teeth is an expected effect due to the bilateral absence of the lateral incisor.

Table 1: Changes of cephalometric measurements from pre-(T1) to post- (T2) treatment

|                | Norm    | T1   | T2   |
|----------------|---------|------|------|
| <b>SNA</b>     | 82° ± 2 | 75.3 | 79   |
| <b>SNB</b>     | 80° ± 2 | 75   | 76.3 |
| <b>ANB</b>     | 2° ± 2  | 0.3  | 2.7  |
| <b>N-A</b>     | 0 ± 3   | -4   | -2   |
| <b>N-Pog</b>   | -4 ± 5  | -4   | -7   |
| <b>Wits</b>    | -1 ± 3  | -5   | -1   |
| <b>SN-GoMe</b> | 32° ± 7 | 35   | 38   |
| <b>FMA</b>     | 25° ± 5 | 30   | 31   |
| <b>Co-A</b>    | 76      | 71   | 78   |
| <b>Co-Gn</b>   | 97-99   | 94   | 97   |

## CONCLUSION

Facemask therapy in growing subjects with Class III malocclusion is effective in the short term. The skeletal modifications induced by the facemask are forward displacement of the maxilla, backward displacement of the mandible, clockwise rotation of the mandibular plane, and counterclockwise rotation of the maxillary plane. When used with the intent to enhance anterior maxillary movement during facemask therapy, preliminary rapid palatal expansion does seem to affect the effectiveness of the orthopedic treatment.



## REFERENCES

- [1] Proffit WR, Fields HW, Ackerman JL, Bailey LJ, Tulloch JFC. 2000. *Contemporary Orthodontics*, Third Edition St. Louis, Toronto, London: The C.V. Mosby Comp.
- [2] Nartallo-Turley PE, Turley PK. Cephalometric effects of combined palatal expansion and facemask therapy on Class III malocclusion. *Angle Orthod*. 1998; 68: 217-224.
- [3] Baccetti E, McGill JS, Franchi L, McNamara JA Jr, Tollaro I. Skeletal effects of early treatment of Class III malocclusion with maxillary expansion and facemask therapy. *Am J Orthod Dentofacial Orthop*. 1998; 113: 333-343.
- [4] Ngan P, Yiu C, Haegg U, Wei SHY. Cephalometric and occlusal changes following maxillary expansion and protraction. *Eur J Orthod*. 1998; 20: 237-254.
- [5] Baccetti T, Franchi L, McNamara JA Jr. Growth in the untreated Class III subject. *Semin Orthod* 2007; 13: 130-42.
- [6] Yea-Hwe Chong, John C. Ive and Jon Årtun. Changes following the use of protraction headgear for early correction of Class III malocclusion. *The Angle Orthodontist* Oct 1996, Vol. 66, No. 5 (October 1996) pp. 351-362.
- [7] Haas AJ. Treatment of maxillary deficiency by opening the midpalatal suture. *Angle Orthod* 1965; 65: 200-17.
- [8] Haas AJ. Palatal expansion: just the beginning of dentofacial orthopedics. *Am J Orthod* 1970; 57: 219-55.
- [9] Starnbach H, Bayne D, Cleall J, Subtelny JD. Facioskeletal and dental changes resulting from rapid maxillary expansion. *Angle Orthod* 1966; 36: 152-64.
- [10] Baik HS. Clinical results of the maxillary protraction in Korean children. *Am J Orthod Dentofacial Orthop* 1995; 108: 583-92.