

**CASE REPORT**

# Two pathological fractures due to mandibular metastasis, rare in colon cancer; a case report presentation

Ufuk ÜNLÜ<sup>1</sup>, Serkan YILDIZ<sup>2</sup>

1. Tokat Gaziosmanpaşa University School of Medicine, Department of Family Medicine, Tokat, Turkey

2. Istanbul Aydın University Faculty of Dentistry, Department of Oral and Maxillofacial Surgery, Istanbul, Turkey

\*Corresponding Authors: Ufuk ÜNLÜ; E-mail: drufukunlu@gmail.com

## Abstract

We reported on 65 years old patient who has colon cancer and referred to our palliative care center with pain due to enlarging metastatic mass on the dorsal of the right hand. She had swelling and numbness on her jaw. Computed tomography (CT) scan was performed for mandible imaging and two pathologic fractures were detected on the right corpus and right condyle of the mandible. Clinicians should consider possible metastases for terminal stage cancer patients.

**Keywords:** Colon Cancer, Mandibular Metastasis, Pathologic Fractures, Condyle of Mandible, Palliative Care

## Introduction

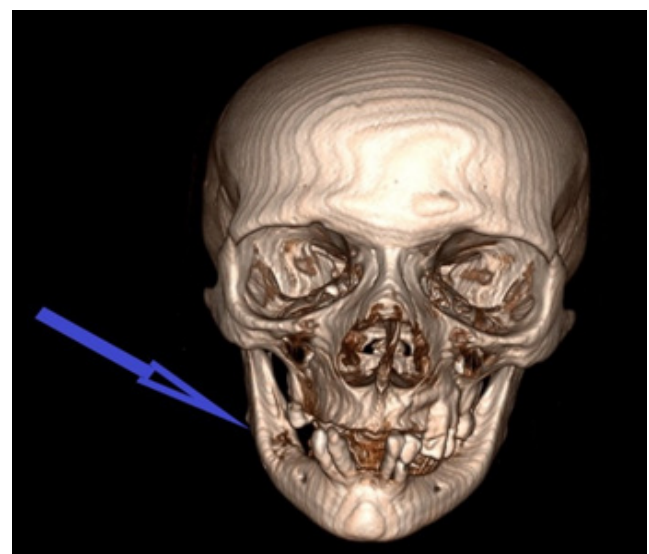
Pathological fractures occur from a very low energy injury or loading forces, which are normally tolerated, in a bone weakened by a pathological condition. These types of fractures can be seen in any bone in entire skeleton. Pathological mandibular fractures are uncommon and represent less than 2% of all mandibular fractures<sup>1</sup>. Metastases to the oral region represent only 1%–3% of all malignant oral neoplasms and the mandible is the most common location<sup>2</sup>. Although lung cancer in men and breast cancer in women are the most common primary origin of metastases; kidney, liver, prostate and colorectal cancer metastases are also observed<sup>3</sup>. Toothache, swelling, and numbness are the most common symptoms<sup>2</sup>.

In this report we aimed to describe the presentation of pathologic mandibular fractures due to metastasis of the colon cancer. It was noticed by a careful anamnesis of a patient presenting with diffuse pain in the body.

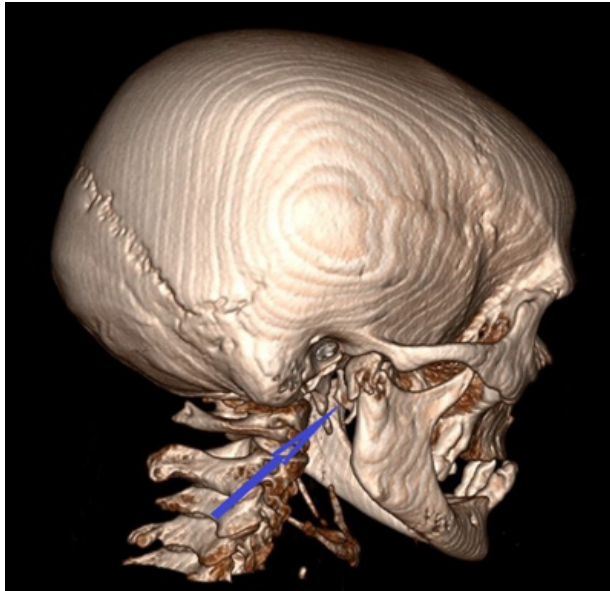
## Case Presentation

65 years old woman was referred to our palliative care centre with common pain, weakness in the legs, and pain due to metastatic bulk on the dorsal of the right hand. In her medical history, she was operated due to colon cancer and performed a colostomy three years ago. After operation she had received 27 cycle chemotherapy. Chemotherapy was discontinued for the patient whose tumour staging was evaluated and metastasises were observed in the vertebra and iliac bones. Then, the patient disrupted his control visits for three months. Patient hadn't received bisphosphonate treatment. In physical examination, there was loss of movement and strength, and numbness in the lower extremities. There was an outward protruding mass of 9x11.5 cm on the dorsal of the right hand. During her detailed anamnesis, it was learned that she had swelling and numbness in his right lower jaw for the past 15 days. On the following 5th day, she heard a cracking sound while eating. In following days swelling and numbness regressed. Computed tomography (CT)

scan was performed for mandible imaging and showed a large destructive lesion in the right corpus of the mandible with soft tissue component with punctate hyperdense calcifications measuring 26x16 mm (Fig 1). In addition, there was a lesion in the right condyle of the mandible that had caused a pathological fracture with a soft tissue component of approximately 8x7 mm, causing more pronounced destruction of the outer cortex of the mandible (Fig 2). At the same time, she received treatment for her neuropathic pains and palliative RT for the mass on the hand. Positron emission tomography-computed tomography (PET-CT) indicated metastasis on the maxilla, mandibular, sternum, vertebrae, sacrum and iliac bones. Palliative radiotherapy was recommended to the patient, who was not scheduled for surgery due to her poor general condition. However, the patient refused treatment.



**Figure 1:** Three-dimensional image of fracture on the right corpus of the mandible detected on CT scan



**Figure 2: Three-dimensional image of fracture on the right condyle of the mandible detected on CT scan**

## Discussion

Colorectal cancer (CRC), which is thought to be preventable, is the third most common diagnosis and second deadliest malignancy. The most frequent sites of metastases in colorectal cancer are liver (57.6%), abdominal lymph nodes (48.3%), and lungs (37.6%).

Metastatic tumours of the oral cavity, which are not common, represent only about 1% of oral tumours. Oral metastases are late and rare complications of common malignant neoplasms. The mandible is the most common location for these metastases. They are seen on the molar area (50%), the premolar area (38%) and the angle or ramus of the mandible (29%)<sup>4</sup>. Metastatic malignancies to the mandibular condyle are extremely rare. These are generally associated with generalized skeletal metastases in the terminal stage of malignant diseases. Multiple myeloma (MM) is another malignancy whose mandibular involvement is a frequent finding. Mandibular fracture may be initial presenting manifestation in MM<sup>5</sup>. Comparing to mandibular corpus, the lack of marrow is thought to be the reason for lower incidence of metastasis to the condyle part<sup>6</sup>.

Pain, swelling, limited mouth opening and paraesthesia are the most common symptoms of pathologic mandibular fractures<sup>2</sup>. However, these symptoms could be ignored by patients who suffer various symptoms of primary malignancies and treatment side effects.

In this report, we present a case of pathological fracture of the mandibular since it has interesting points. The primary diagnosis of our patient was colon cancer which has rare

mandibular metastasis. Our patient's application complaint was not related to mandible fracture. Swelling and pain in the jaw had been regressing at the time of admission. Pathological fractures of the mandibular was detected with CT performed due to clinical suspicion. Two pathological fractures in the right corpus and right condyle of the mandible were seen on CT. Another interesting feature of this case was the fact that one of the fractures was on the condyle which is a rare location for pathological mandibular fractures. Surgical operation was not considered for the patient with widespread metastases and short life expectancy.

## Conclusion

We emphasize the importance of physical examination, detailed and careful anamnesis in palliative care in approaching to terminal stage cancer patients. Cancer patients with heavy symptoms may overlook their complaints such as pain and numbness in especially unusual regions. Also, clinicians should consider possible metastases in such patient groups and determine treatment methods.

## References

1. AlGahtani M, Alqudah M, AlShehri S, et al. GKB Pathologic Fracture of the Mandible Caused by Metastatic Follicular Thyroid Carcinoma. *Journal of the Canadian Dental Association* 2009 (75):6; 457-460. PMID: 19627656
2. Salvador JC, Rosa D, Rito M, Borges A. Atypical mandibular metastasis as the first presentation of a colorectal cancer. *BMJ Case Rep*. 2018;2018:bcr2018225094. DOI: 10.1136/bcr-2018-225094
3. Steffen C, Doll C, Thieme N, et al. Presentation of cervical metastases and pathological mandibular fracture due to pulmonary adenocarcinoma: A case report. *Int J Surg Case Rep*. 2020;70:53-55. DOI: 10.1016/j.ijscr.2020.04.044
4. Romanet I, Lan R, Ordioni U, et al. A rare case of oral metastasis of colon adenocarcinoma. *J Stomatol Oral Maxillofac Surg*. 2018;119(3):229-231. DOI: 10.1016/j.jormas.2018.02.003
5. Moura LB, Gabrielli MF, Gabrielli MA, Filho VA. Pathologic Mandibular Fracture as First Sign of Multiple Myeloma. *J Craniofac Surg*. 2016;27(2):e138-e139. doi:10.1097/SCS.0000000000002386
6. Kruse AL, Luebbers HT, Obwegeser JA, et al. Temporomandibular disorders associated with metastases to the temporomandibular joint: a review of the literature and 3 additional cases. *Oral Surg Oral Med Oral Pathol Oral Radiol Endod*. 2010;110(2):e21-8. <https://doi.org/10.3892/ol.2017.6951>