

# *Cloacogenic Adenocarcinoma of the Vulva: Case Report*

*Özben Yalçın<sup>1\*</sup>  
Yalçın Polat<sup>2</sup>  
Erdin İlter<sup>3</sup>  
Ş. Sinem Özbey<sup>1</sup>  
Duygu Düşmez Apa<sup>2</sup>*

## **Abstract**

Primary villoglandular adenocarcinomas of the vulva are rare. Hypotheses about the origin of this neoplasm remains highly speculative. We reported the case of a 51-year-old woman with this very uncommon malignant tumor. Immunohistochemical studies of the tumor revealed positive staining for cytokeratins 7 and 20 and negative staining for estrogen and progesterone receptors. Special stains showed the presence of intracellular mucin. No other primary lesion was found on clinical evaluation and extensive investigation. The patient was treated by radical hemivulvectomy. The patient remained disease free for 16 months after the initial surgery.

**Keywords:** *vulva; cloacogenic carcinoma; histopathology; immunopathology.*

Vulvanın kloakojenik adenokarsinomu: olgu sunumu

## **Özet**

Vulvanın primer villoglandüler adenokarsinomu çok nadir görülen bir antitedir. Bu neoplazinin kökenine ait hipotezler ise son derece spekülatiftir. Olgumuz, 51 yaşında kadın hastada saptanan bu çok nadir malign tümörün bir örneği olup, immünohistokimyasal çalışmalarda tümör hücrelerinin sitokeratin 7 ve 20 ile pozitif boyandığı, östrojen ve progesteron reseptörleri ile ise reaktivite olmadığı gözlenmiştir. Histokimyasal incelemeler ile intraselüler müsin saptanmıştır. Klinik muayene ve detaylı araştırma sonucu hastada başka herhangi bir primer lezyon olmadığı kanıtlanmıştır. Hasta radikal hemivulvektomi ile tedavi edilmiş olup cerrahi sonrası 16. ayda hastalıksız olarak takip edilmektedir.

**Anahtar kelimeler:** *vulva, kloajenik karsinom, histopatoloji, immünopatoloji*

\*Corresponding Author ozbena@yahoo.com

<sup>1</sup> Okmeydani Research and Education Hospital, Department of Pathology

<sup>2</sup> Maltepe University Department of Pathology.

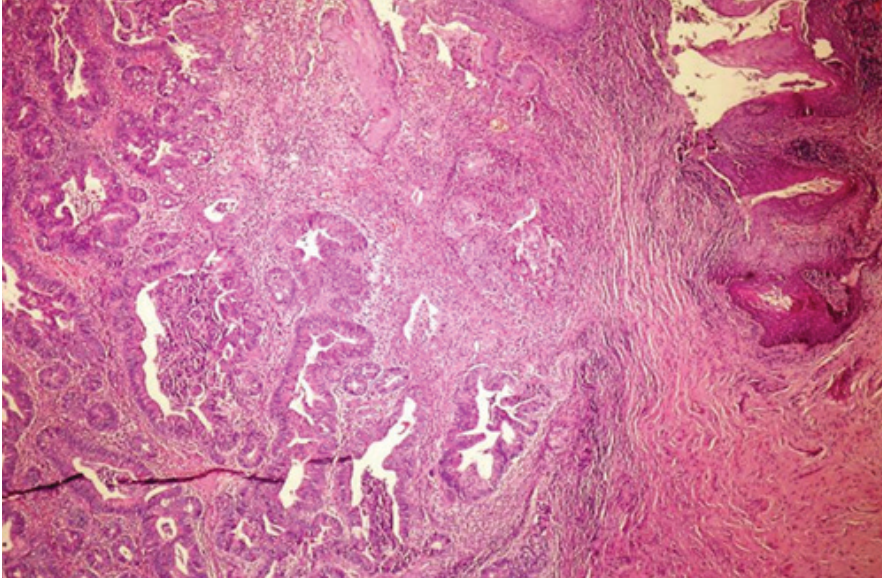
<sup>3</sup> Maltepe University Department of Obstetrics And Gynecology

## **INTRODUCTION**

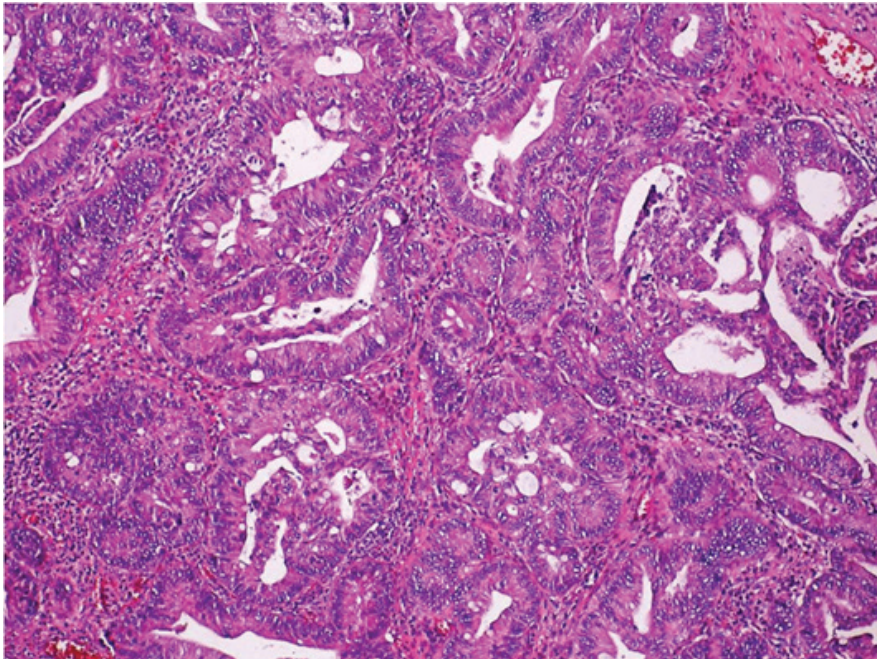
Primary adenocarcinomas of the vulva are rare, and most arise from Bartholin's glands (1). The villoglandular adenocarcinoma of colonic type is a rare variant of vulvar adenocarcinoma, and only seven cases have been reported (2). The possibility that those tumors may originate from cloacal remnants has been raised (3). We report an additional case with this rare disease.

## **CASE REPORT**

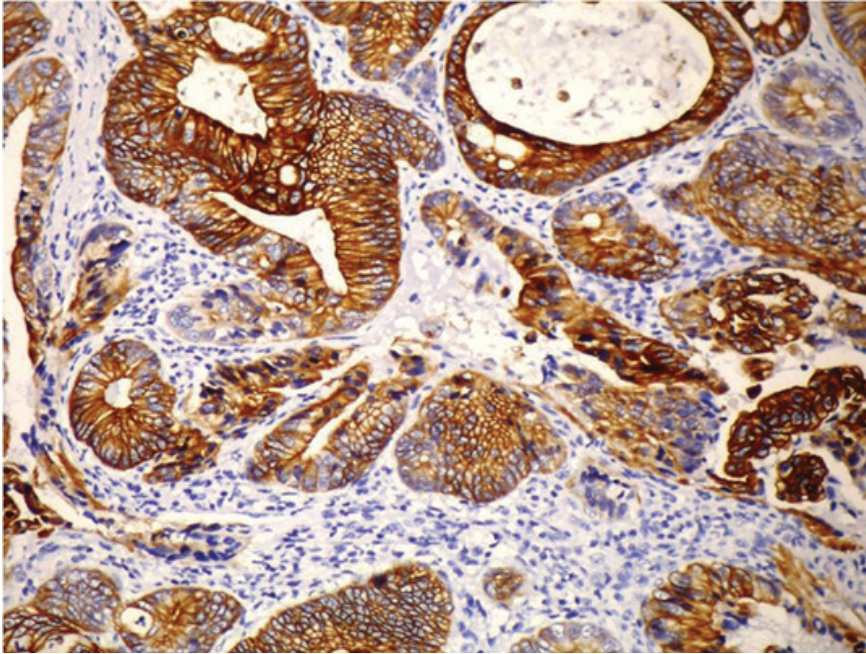
A 51 years old woman, consulted her physician for a vulvar lump with mild local discomfort and burning. She had no relevant medical history. On physical examination, a 2-cm nodular reddish lesion on the inferior aspect of the right labia majora at 1.5 cm distance from the perineum was seen and no other vulvar lesions were observed. Also there were no lesions in the cervix, vagina or anal/perianal region. Uterus was small and the adnexa were not palpable. Rectal examination, proctoscopy and cystoscopy revealed no abnormalities. A complete clinical investigation was performed. Serum CA19-9, carcinoembryonic antigen and CA125 levels, as well as complete blood count and hepatic enzymes levels (aspartate aminotransferase, alanine aminotransferase, gamma-glutamyltransferase, alkaline phosphatase, and bilirubin) were within the reference range. Chest X-ray, mammogram, colonoscopy and abdominal ultrasonography were also normal. Microscopic examination of paraffin-embedded sections disclosed a well-circumscribed and well-differentiated adenocarcinoma of colonic type. Adenocarcinoma showed indirect continuity with the epidermis (Fig 1). The surface presented a villoglandular aspect that is partially lined by mucin-secreting cells with rare interspersed goblet-type cells (Fig 2). The tumor cells showed moderate to strong staining for cytokeratin 7 (Fig 3) and for cytokeratin 20 (Fig 4). However, nuclear progesterone and estrogen receptors are negative. The neoplastic cells contained mucin as shown by positive staining with Alcian blue and had a diastase-resistant reaction shown by periodic acid-Schiff. Two weeks later, the patient was treated by radical hemivulvectomy with surgical margins of at least 1 cm in width. She remained well and disease free for 16 months after surgery.



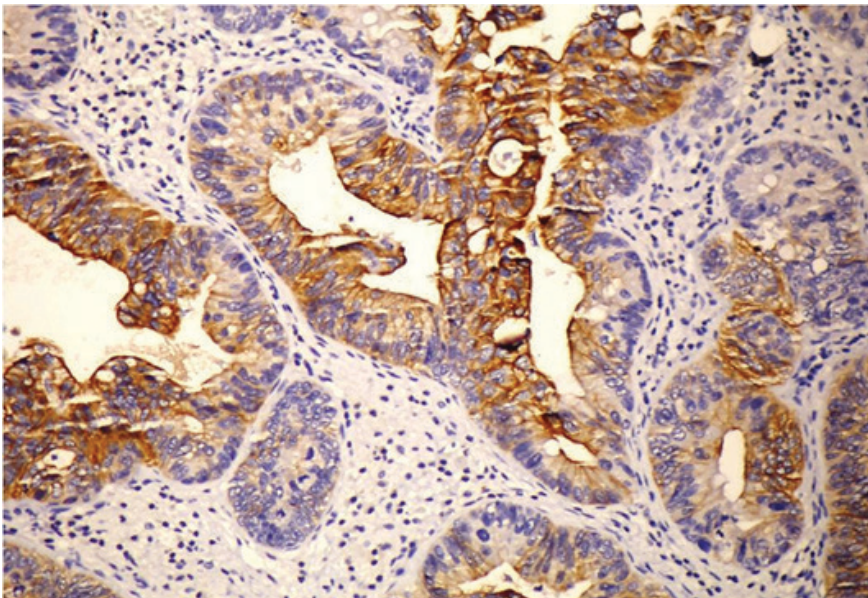
**Figure 1.** Tumor is indirectly continuous with the epidermis



**Figure 2.** Tumor which has a villoglandular growth pattern is composed of musin secreting cells and rare goblet type cells.



**Figure 3.** Tumor cells are positive with cytokeratin 7.



**Figure 4.** Tumor cells are positive for cytokeratin 20.

## **DISCUSSION**

Primary adenocarcinomas of the vulva are rare, but most arise from Bartholin's glands. Unlike our case, Bartholin's glands adenocarcinomas are deeply infiltrative and an in situ component is usually present in the adjacent benign glands (4). A sweat gland origin is also unlikely because these adenocarcinomas lack the typical villoglandular pattern and do not contain diastase-resistant Periodic acid–Schiff material (1). A paraurethral Skene's gland or minor vestibular gland origin has also been excluded because the tumor was located away from the introitus and the urethra in our case. The possibilities of adenocarcinoma arising from ectopic breast tissue, sebaceous glands and endometrium were ruled out by the histopathologic and immunohistochemical features of our patient's lesion. In our case, we also excluded the possibility of metastatic carcinoma by the absence of any known primary lesions with clinically and historically detailed evaluation of the gastrointestinal tract, breast and lungs for an evidence of any primary tumor.

The cellular origin of these tumors is still unclear; but, it has been proposed that they may arise from the remnant cells of the cloacal membrane (5).

The treatment for many cases is radical vulvectomy and bilateral local lymph node excision (6).

In majority of the cases, tumor did not metastasized and was referred to as nonaggressive and the excision of the lesion(s) is appeared to be curative (6-9). However, Willen et al. (5) reported recurrence within a year and a wider resection was necessary. Also, Rajni et al. reported an aggressive tumor, with metastatic spread to inguinal and pelvic lymph nodes and the lung. (10).

Most of the cases reported were to be single tumor arising indirect continuity with the surface epithelium (5,8) such as in our case.

Primary cloacogenic carcinoma of the vulva is very rare but it is important for the pathologist and clinician to be aware of this entity. Any lesion seen on vulva and perineum should be biopsied immediately and the biopsy should be reviewed by the pathologist for confirmation of diagnosis.

Detailed clinical work-up and careful morphological examination by histopathology and immunohistochemistry are necessary for early diagnosis and less radical management. Early diagnosis and wide local excision of the tumor(s), prior to metastatic spread, is very important for good prognosis and decreasing recurrence rate.

## REFERENCES

- [1] Nasir S, Zaidi H, Conner MC. Primary vulvar adenocarcinoma of cloacogenic origin. *South Med J* 2001; 94:744-746.
- [2] Rodriguez A, Isaac MA, Hidalgo E, et al. Villoglandular adenocarcinoma of the vulva. *Gynecol Oncol* 2001; 83:409-411,
- [3] Wilkinson EJ: Premalignant and malignant tumors of the vulva. In: Kurman RJ editor. *Blaustein's Pathology of the Female Genital Tract*, New York: 5th edition., Springer-Verlag, 2002, pp 122-8
- [4] Kennedy JC, Majmudar B. Primary adenocarcinoma of the vulva, possibly cloacogenic. A report of two cases. *J Reprod Med* 1993; 38:113-116.
- [5] Willen R, Békássy Z, Carlén, B., et al. Cloacogenic adenocarcinoma of the vulva. *Gynecologic Oncology* 1999; 74, 298-301.
- [6] Zaida SNH, Conner MG. Primary vulvar adenocarcinoma of cloacogenic origin. *Southern Medical Journal* 2001; 94, 744-746.
- [7] Dube V, Veilleux C, Plante M, et al. Primary villoglandular adenocarcinoma of cloacogenic origin of the vulva. *Human Pathology* 2004; 35, 377-379.
- [8] Lui SH, Ho CM, Huang, SH., et al. Cloacogenic adenocarcinoma of the vulva presenting as recurrent Bartholin's gland infection. *Journal of the Formosan Medical Association* 2003; 102, 49-51.
- [9] Vale'Rie Dube, Chantal Veilleux, Marie Plante, Bernard TeTu. Primary villoglandular adenocarcinoma of cloacogenic origin of the vulva. *Hum Pathol* 35:377-379. 2004
- [10] Rajni c, Kimberly A, Wood CK, Giede AA, Unusually aggressive primary cloacogenic carcinoma of the vulva: Case Reports in *Clinical Medicine* 2013; 2 (5): 302-305

# ***Tuberositas Tibia Avulsiyon Kırığının Tedavisinde Paratenonun Önemi: Olgu Sunumu***

***Kürşat Aytekin<sup>1\*</sup>***  
***Cem Zeki Esenyel<sup>1</sup>***

## **Özet**

Tuberositas tibia (TT) avulsiyon kırıkları genellikle adölesanlarda gözlenen fiz yaralanmalarıdır. Çoğunlukla spor yaralanmaları olarak karşımıza çıkarlar. Bu olgu sunumunda futbol maçı esnasında TT avulsiyon kırığı geçiren ve cerrahi ile tedavi edilen bir olguyu sunmayı hedefledik. Hastamızda, literatürden farklı olarak paratenondan ayrışan patellar tendon, TT'nin tespiti sonrası sağlam kalmış olan paratenonun altına tespit edilmiştir. Hastanın takiplerinde herhangi bir komplikasyon gözlenmemiştir. İyileşme sonunda TT'de hipertrofi veya patellar tendonda kalsifikasyon gibi herhangi bir komplikasyon gözlenmemesi paratenondan ayrışmış olan patellar tendonun sağlam kalan paratenon altına tespiti ile ilgili olabilir.

***Anahtar kelimeler:*** *tuberositas tibia, avulsiyon kırığı, paratenon*

## **Importance of Paratenon in the Treatment of Avulsions of Tuberositas Tibia: Case Report**

### **Summary**

Tuberositas tibia (TT) avulsion fractures are the injuries usually observed in adolescents. They often come out as sports injuries. In this case report, we aimed to present a case of TT avulsion fracture which occurred during the football game and was treated with surgery. Unlike the literature, the patellar tendon, which separated from the paratenon, was fixed below the paratenon which had remained intact after the separation of TT. No complication was observed in the patient's follow-up. At the end of recovery, no complication such as hypertrophy in TT or calcification in patellar tendon was observed. Any complication seen may be related to the

<sup>1</sup> Giresun Üniversitesi Tıp Fakültesi, Ortopedi ve Travmatoloji AD

\* Sorumlu yazar: kursadaytekin@gmail.com